

SHORT COMMUNICATION

Liver Histopathological Studies of Mice (*Mus musculus* sp.) Infected With Gamma Rays Irradiated *Plasmodium berghei* Strains Anka

TUR RAHARDJO, SITI NURHAYATI, DWI RAMADHANI*

Center for Technology of Radiation Safety and Metrology, National Nuclear Energy Agency of Indonesia,
Jalan Lebak Bulus Raya No. 49, Kotak Pos 7043 JKSKL, Jakarta 12070, Indonesia

Received February 25, 2013/Accepted July 19, 2013

Malaria is a serious global disease and a leading cause of morbidity and mortality in tropical and sub-tropical countries. Radiation attenuated vaccines have been demonstrated to be an effective means of controlling certain parasitic infections such as malaria. Our previous research showed that irradiation dose of 150-175 Gy to *Plasmodium berghei* were able to suppress the infected erythrocyte cells and irradiation dose at 150 Gy was more effective compared to 175 Gy in attenuate the parasites based on parasitemia index. Aim of this research was to investigate the most suitable irradiation dose to attenuated *P. berghei* based on the the histological changes in the liver mouse malaria model. Histological changes in mice liver because of Plasmodium is congestion in the sinusoids and masses of hemozoin. Fourty Swiss mice were randomly assigned to four equal groups. First group of mice were inoculated with the unirradiated malaria parasites as a positive control while negative control group represented uninfected normal control. The third group of mice was inoculated with the irradiated malaria parasites with dose 175 Gy. Last group were inoculated with the irradiated malaria parasites with dose 150 Gy. Mice were sacrificed at day 6, 8, 12, 16, 20, and 24 post inoculation for liver histological study. Their livers processed for histomorphometric assessment of sinusoidal area, haemozoin area and hepatosomatic index as a quantitative measure of altered morphology. Hepatic sinusoidal area in mice infected with the unirradiated malaria parasites increased by 104% in day 24 post inoculated compared to day 6 post inoculated, whereas a smaller increase of 46% occurred in mice that were inoculated with the irradiated malaria parasites with dose 150 Gy. The difference between positive control and 150 Gy group was significant ($P < 0.05$). The highest average haemozoin area in all days post inoculation was in positive control whereas a smaller occurred in mice that were inoculated with the irradiated malaria parasites with dose 175 Gy, but the different was not significant ($P > 0.05$). For hepatosomatic index (HSI) at day 24 post inoculation the HSI value in group 150 Gy (5.33) was the smallest compared to other groups. Based on our research it can be concluded that irradiation dose at 150 Gy was more effective compared to 175 Gy in attenuate the parasites based on assessment of sinusoidal area, and HSI value at 24 day post inoculation.

Keywords: gamma rays, histopathology, liver, *Mus musculus*, *Plasmodium berghei*

INTRODUCTION

Malaria remains one of the major public health problems in the developing world, with an estimate of 300-500 million cases and 1-3 millions deaths every year. The development of a vaccine has been one of the research strategies to face this threat, especially with the spreading of parasite resistance to many of the drugs currently available to treat the disease (Carvalho *et al.* 2002). In 1967 it was shown that immunizing mice with irradiated rodent malaria (*Plasmodium berghei*) sporozoites protected the

mice against malaria (Nussenzweig *et al.* 1967). By the early 1970s it had been shown that humans could be protected against malaria by immunization using the bite of irradiated mosquitoes infected with *P. falciparum* sporozoites (Clyde *et al.* 1973; Rieckmann *et al.* 1979). There is now a major effort to develop a radiation-attenuated *P. falciparum* whole sporozoite vaccine. The radiation attenuates the sporozoites, preventing them from fully developing in hepatocytes (Hoffman & Chattopadhyay 2008).

Radiation attenuated vaccines have been demonstrated to be an effective means of controlling certain parasitic infections such as malaria. Although many parasitic diseases are known to produce a high degree of acquired immunity, it has been impossible

*Corresponding author. Phone: +62-21-7513906/7659511,
Fax: +62-21-7657950, E-mail: dhani02@batan.go.id

in the past to reproduce this immunity using artificially prepared vaccines, with the striking exception being the radiation attenuated vaccines. The successful use of irradiated plasmodium as a vaccine depends on finding a radiation dose which will significantly reduce the pathogenic effect of the larvae without seriously impairing their immunogenic power (Syaifudin *et al.* 2011).

It is thought that the amount of radiation required to render the parasites nonviable is about 150 Gy for an inoculum of certain number of parasites (Luke & Hoffman 2003). Our early research showed that irradiation dose of 150-175 Gy to *P. berghei* were enable to suppress the infected erythrocyte cells and further supported by the facts that we found a long prepatent phase and low parasitemia index (Tetrian & Darlina 2007). Moreover, our recent work showed that irradiation dose at 150 Gy was more effective compared to 175 Gy in attenuated the parasites based on parasitemia index (Nurhayati 2011). Aim of this research was to investigate the most suitable irradiation dose to attenuated *P. berghei* based on the histological changes in the liver of mouse malaria model. The liver is of great interest in malaria parasitemia for at least three reasons. Firstly, it is a target organ that plays a key role in the parasite's developmental cycle. Secondly, parasite activity combine with the host's immune response to give rise to chronic inflammatory insults which predisposes the organ to deleterious conditions including dysfunction and fulminant hepatic failure, as well as hepatocellular cancer, and non-alcoholic fatty liver disease. Thirdly, understanding of the liver stage of malaria parasites offers a promising target for antimalarial strategies that aim to establish immunity against the malaria parasite (Aidoo *et al.* 2012).

Mouse, just as in humans, has a liver with four major lobes, and a gall bladder (which is absent in rat), making it a good model for the study being reported here. Moreover, *P. berghei* (murine malaria) is one of the most widely used experimental models to study malaria transmission. One striking histological feature of the acute stage of malarial parasitemia is gross congestion in the sinusoids and hypertrophy of hepatic macrophages (Kupffer cells) that arises as they engulf parasitized and unparasitized red blood cells, remnants of parasites, granules and masses of hemozoin containing hemosiderin (Baheti *et al.* 2003; Helegbe *et al.* 2011; Aidoo *et al.* 2012).

MATERIALS AND METHODS

Parasites. *Plasmodium berghei* strain ANKA was obtained from the *Eijkman Institute* for

Molecular Biology and the *Center for Biomedical and Basic Technology of Health*, Ministry of Health Republic of Indonesia. Proliferation of the parasite is done *in vivo* by infecting parasites into the body of Swiss strain mice in Biomedical Group laboratory animals at Center for Radiation Safety and Metrology Technology, National Nuclear Energy Agency of Indonesia.

Mice. Male Swiss strain mice (supplied by Ministry of Health Republic of Indonesia) was used in this study. Four to six weeks old mice, which were almost 20 g in weight, were housed at room temperature (20-23 °C) on a 12 h light and 12 h dark cycle, with unlimited access to food and tap water.

Experimental Design. Total of 40 mice were randomly divided into four groups: 0 Gy as a positive control, 175 Gy, 150 Gy, and negative control. Mice in 0 Gy group were inoculated with the unirradiated malaria parasites while mice in negative control group represented uninfected normal control. Mice in 175 Gy group were inoculated with the irradiated malaria parasites with a dose of 175 Gy, and the ones in 150 Gy group were inoculated with the irradiated malaria parasites with a dose of 150 Gy. The mice were injected intraperitoneally with standard inoculum of 1×10^7 irradiated *Plasmodium berghei* ANKA at erythrocytic stage on the first day (day 0). Irradiation was conducted using a gamma irradiator (Cobalt-60 of IRPASENA) of the Center for Application of Isotope and Radiation, National Nuclear Energy Agency of Indonesia, with a dose of 0, 150, and 175 Gy. The mice were sacrificed at day 6, 8, 12, 16, 20, and 24 post inoculation for liver histological study.

Ethical Considerations. Experiments with animals were conducted according to the ethical standards formulated in Annex Regulation, Head of National Nuclear Energy Agency of Indonesia, Number: 195/KA/XI/2011, Date: 11 November 2011, and all measures were taken to protect the animals from pain or discomfort. This standard has been approved by the ethical review board of National Nuclear Energy Agency of Indonesia.

Location and Duration of Study. This study was conducted in the Biomedical Group laboratory animals at Center for Radiation Safety and Metrology Technology, National Nuclear Energy Agency of Indonesia. Animal acclimatization, histological studies, and evaluation of results were lasted for four months (November 2009 to February 2010).

Histological Study. Mice livers were fixed in 10% formalin until ready to be used. After fixation, livers were cut in transversal sections. These specimens were suspended in absolute alcohol, absolute xylene for 4 days, and then embedded in

paraffin. Sections were cut at 7 μm , stained with hematoxylin–eosin (HE) and analyzed by light microscopy. The photomicrographs of the relevant stained sections were taken with the aid of a light microscope.

Hepatosomatic Index. The hepatosomatic index (HSI) was determined by dividing the liver weight of each mouse by its respective body weight at termination of experiment. Mice were sacrificed on day 24 post inoculation after first anesthetizing them with chloroform in a tight fitted jar. Freshly dissected liver was put in ice-cold physiological saline to wash-off blood, and blotted dry with filter paper. The liver was then weighed (in grams) using the Mettler balance. Two weight readings were taken for each liver and the average was determined.

Image Acquisition. A Nikon Biophot microscope attached with Nikon D3000 digital single lens reflects (DSLR) camera system was used to capture images of the smears. The slides were examined under 40 \times objective lens. Images were captured at a resolution of 1936 \times 1296 and saved as JPEG files.

Image Analysis. A plugin and macro for measuring the haemozoin and sinusoid area in liver histology was developed. For measuring the haemozoin area in images that were captured by conventional light microscope, an ImageJ 1.47 plugin that already developed in our previous works was used (Ramadhani *et al.* 2012). Total of 350 random liver histology images were analyzed using our plugin and macro in ImageJ 1.47. ImageJ is a public domain Java image processing program inspired by NIH Image for the Macintosh. It runs on any computer with a Java 1.1 or later virtual machine, either as an online application or as a downloadable application.

Statistical Analysis. Data analysis was done using the Microsoft Excel and StatPlus (Statistical Analysis Software) Version 2.0. Statistical significance of the difference between group means was performed by Student's t test with $P < 0.05$ were considered to have a statistically significant different.

RESULTS

Haemozoin Area. Haemozoin was not observed at day 6 post inoculation in all groups. Haemozoin started to appear at day 8 in positive control and at day 12 after the inoculation in group of mice that was inoculated with the irradiated malaria parasites with a dose of 150 Gy (Table 1). In 175 Gy group that was inoculated with the irradiated malaria parasites with a dose of 175 Gy, haemozoin started to appear at day 20 after the inoculation. The highest haemozoin area value in positive control was in day

24 post inoculation (3387.99 μm^2) (Figure 1). In 150 Gy group, the highest haemozoin area value was in day 16 post inoculation (3127.98 μm^2).

Sinusoid Area. Our research showed that sinusoid area in liver histology was increased in all groups that infected with *P. berghei* (Table 2). Hepatic sinusoidal area in mice infected with the unirradiated malaria parasites increased by 104% in day 24 post inoculation compared to day 6 post inoculation, whereas a smaller increase of 46% occurred in mice that were inoculated with the irradiated malaria parasites with a dose of 150 Gy. In 175 Gy group, the sinusoid area in all days post inoculation was higher compared to group 150 Gy.

Table 1. Haemozoin area in four group at 6, 8, 12, 16, 20, and 24 post inoculation

Radiation doses	Days post inoculation	Haemozoin area (μm^2)
0 Gy (positive control)	6	0
	8	3235.8694
	12	1492.6904
	16	2262.9130
	20	2295.3721
150 Gy	6	0
	8	0
	12	228.95110
	16	3127.9867
	20	2747.0502
175 Gy	6	0
	8	0
	12	0
	16	0
	20	2066.4166
Negative control	6	0
	8	0
	12	0
	16	0
	20	0
	24	0

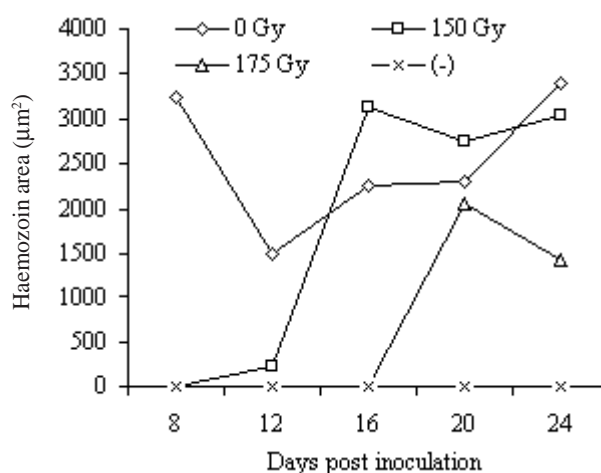


Figure 1. Haemozoin area graph in all experimental groups.

The highest sinusoid area in positive control was in day 16 post inoculation (26884.7796 μm^2) (Figure 1). In 150 Gy group, the highest sinusoid area was in day 20 post inoculation (9852.4288 μm^2). In 175 Gy group the highest sinusoid area was in day 24 post inoculation (48881.0422 μm^2), and it was also the highest sinusoid area in all groups (Figure 2).

Hepatosomatic Index. The mean HSI obtained from two mice on day 24 post inoculation was 8.83 in positive control group, 5.33 in 150 Gy experimental group, 7.46 in 175 Gy experimental group and 5.35 in negative control group (Figure 3). Our research showed that the HSI value in 150 Gy was better than in 175 Gy because almost gave the same value compared to negative control.

Statistical Analysis. Statistical analysis using t-test in sinusoidal area between 150 Gy group

compared to positive control showed that there was a significant different ($P = 0.002$), because the p-value is smaller than 0.05 (Table 3). Contrary with that in 175 group, the sinusoidal area was not significantly different when it was compared to positive control because the p-value was higher than 0.05 ($P = 0.352$) (Table 4). For the average haemozoin area, the smallest value was in 175 Gy group (1753.486 μm^2), and second smallest one was in 150 Gy group (2283.565 μm^2).

Table 2. Sinusoid area in four group at 6, 8, 12, 16, 20, and 24 post inoculation

Radiation doses	Days post inoculation	Sinusoid area (μm^2)
0 Gy (Positive control)	6	12999.1828
	8	9499.0036
	12	21577.1900
	16	26884.7796
	20	25740.4912
150 Gy	6	2952.6814
	8	3182.6630
	12	3739.3089
	16	4547.1649
	20	9852.4288
175 Gy	6	3839.2609
	8	4998.2209
	12	9544.0266
	16	9450.4178
	20	9507.1772
Negative control	24	48881.0422
	6	3169.3070
	8	3965.9780
	12	2924.7930
	16	3346.7630
	20	3418.1820
	24	4083.4480

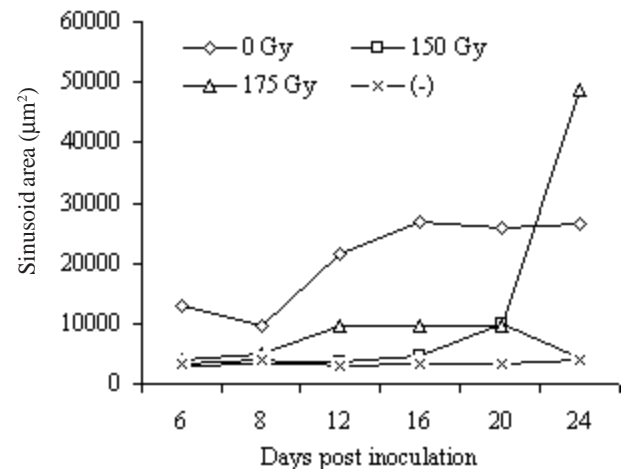


Figure 2. Sinusoid area graph in all experimental groups.

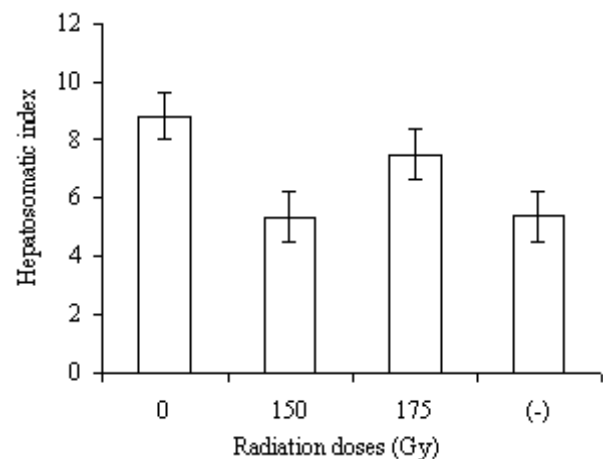


Figure 3. HSI value at all experimental groups.

Table 3. t-test analysis in sinusoidal area between 150 Gy group compared to positive control

t-test analysis									
	N	Mean	Std. Dev	Std. Err	t	df	p-value	lower 95%	upper 95%
Difference	6	15.773	6.497	2.652	5.947	5	0.002	8.954	22.591

Table 4. t-test analysis in sinusoidal area between 175 Gy group compared to positive control

t-test analysis									
	N	Mean	Std. Dev	Std. Err	t	df	p-value	lower 95%	upper 95%
Difference	6	17.054	7.568	3.089	5.519	5	0.003	9.111	24.997

DISCUSSION

Our research showed that irradiation dose at 150 Gy was more effective compared to 175 Gy in attenuate the parasites based on the assessment of sinusoidal area and HSI value at 24 day post inoculation. The average sinusoidal area at 150 Gy group in all days post inoculation was the lowest ($4766.28 \mu\text{m}^2$) compared to 175 Gy group (Figure 4). In day 24 post inoculation at 175 Gy group the highest sinusoidal area was recorded, which can be seen in Figure 5A. Higher sinusoidal area represents the dilated hepatic sinusoids. As showed by Shittu *et al.* (2011), liver tissues obtained from untreated mice infected with *P. berghei* in positive control group showed dilated hepatic sinusoids congested with hypertrophied, K upffer's cells-laden malaria pigment and parasitized red blood cells (Figure 5B).

Interestingly in this research, the haemozoin in 150 Gy experimental group already can be identified at day 12 post inoculation. Contrary with that in 175 Gy group, the haemozoin started to appear at day 20

post inoculation. Based on the average of haemozoin area, it was found that in 175 Gy group better than 150 Gy group. Haemozoin area is usually ingested by tissue macrophages and present in the bone marrow or in Kupffer cells, the resident macrophages of the liver. Haemozoin (malaria pigment) is a disposal product formed from the digestion of red blood cells by malaria parasites, and it is observed in either the cytoplasm or outside hepatocyte and Kupffer cells as black or brownish granules. Haemozoin is can be seen more frequently in the spleen than in liver. In this research, we identified the haemozoin using conventional light microscope. Because it is a birefringent (doubly refracting) substance, it is significantly more visible when viewed using crossed polarized light (Lawrence & Olson 1986). This viewing is possible if one uses a polarizing microscope that uses two polarizing filters at right angles to each other, one between the light source and the slide and the other between the slide and the observer. In one study examining histological specimens, the sensitivity of polarizing microscopy for malaria parasites was almost double that of conventional light microscopy although inoculations detected by polarizing microscopy were false positives results (Romagosa *et al.* 2004).

In the next research, we plan to measure the haemozoin area in the images that obtain from simple low cost polarizing microscope. Maude *et al.* (2009) devised a simple method for adapting a conventional light microscope for polarized light microscopy for as little as \$10 U.S. dollars. Although the result does not match the high-precision optics of a purpose built instrument, they found it was perfectly adequate for detecting malaria pigment (Maude *et al.* 2009). In one study examining histological specimens, the

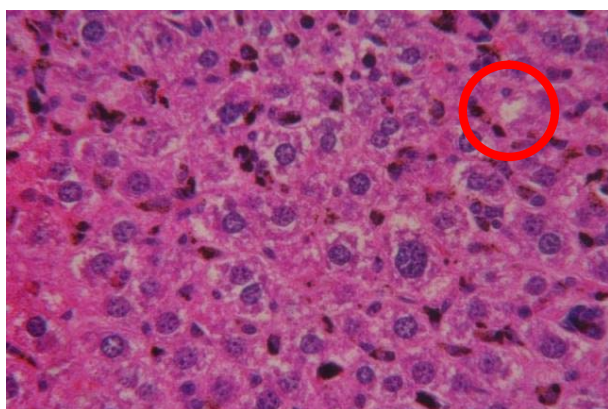


Figure 4. Sinusoid dilatation (red circle) in day 24 post inoculation at 150 Gy group.

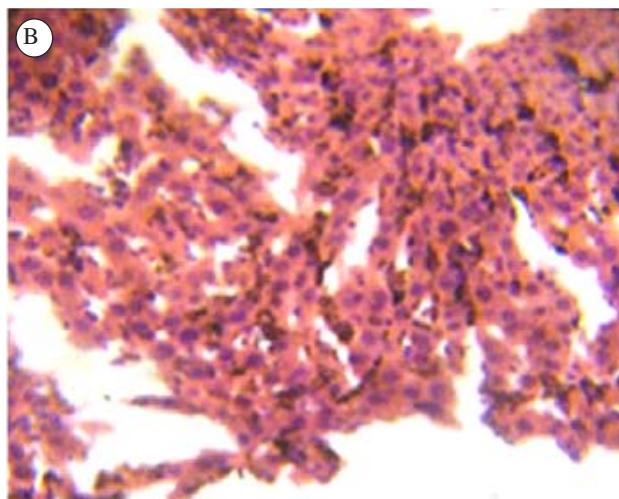
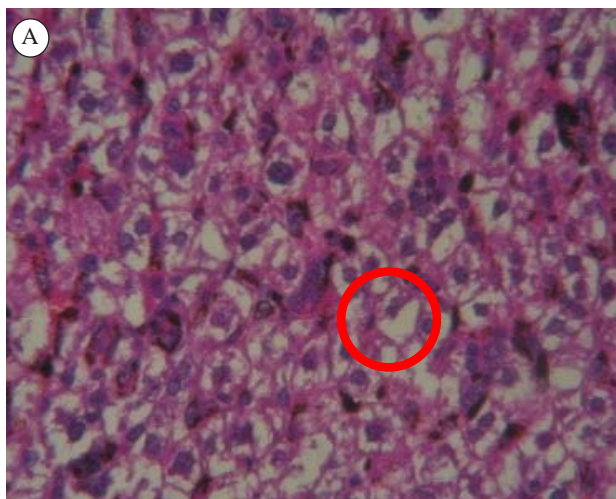


Figure 5. A. Sinusoid dilatation (red circle) in day 24 post inoculation at 175 Gy group; B. Liver tissues section obtained from untreated mice infected with *P. berghei* in Shittu *et al.* (2011).

sensitivity of polarizing microscopy for malaria parasites was almost double that of conventional light microscopy although inoculations detected by polarizing microscopy were false positives results (Romagosa *et al.* 2004). These false-positive positive results occurred because dust and dirt on the slide which sometimes produce a birefringence similar to that of haemozoin, although this can usually be avoided by double-checking the pigment containing cells for parasites by using light microscopy. Polarizing microscopy has also been used to quantify past episodes of placental malaria in placental blood smears, and related method using a depolarized laser has been tested for automated detection of malaria in peripheral blood by flow cytometry (Mendelow *et al.* 1999; Kramer *et al.* 2001).

Results obtained from this research support our previous work that irradiation dose at 150 Gy was more effective compared to 175 Gy in attenuate the parasites, since tissue biopsy may be a valuable tool to establish diagnosis when other diagnostic methods are inconclusive considering the fact that histopathological alterations due to malarial inoculation in the liver are specific (Shittu *et al.* 2011). Radiation can attenuate the *P. berghei* and as a consequence *P. berghei* were unable to promote the hepatic injury. Haque *et al.* (2011) indicates that parasites are the major promoters of hepatic injury in malaria mice model. They also support the idea that *P. berghei* ANKA inoculation causes a parasite-driven multiorgan disease (Haque *et al.* 2011).

ACKNOWLEDGMENT

The authors are greatly obliged to Mukh Syaifudin, Center for Technology of Radiation Safety and Metrology, National Nuclear Energy Agency of Indonesia for the critical reading of the manuscript. The valuable technical assistance of Devita Tetriana is gratefully acknowledged.

REFERENCES

- Aidoo E, Addai FK, Ahenkorah J, Hottor B, Bugeyi KA, Gyan BA. 2012. Natural cocoa ingestion reduced liver damage in mice infected with *Plasmodium berghei* (NK65). *Research and Reports in Tropical Medicine* 3:107-116.
- Baheti R, Laddha P, Gehlot RS. 2003. Liver Involvement in Falciparum Malaria A Histo-pathological Analysis. *Journal, Indian Academy of Clinical Medicine. JIACM* 4:34-38.
- Carvalho LJM, Daniel Ribeiro CT, Goto H. 2002. Malaria vaccine: candidate antigens, mechanisms, constraints and prospects. *Scand J Immunol* 56:327-343. <http://dx.doi.org/10.1046/j.1365-3083.2002.01160.x>
- Clyde DF, Most H, McCarthy VC, Vanderberg JP. 1973. Immunization of man against sporozoite-induced falciparum malaria. *Am J Med Sci* 266:169-177. <http://dx.doi.org/10.1097/0000441-197312000-00001>
- Haque A, Best SE, Amante FH, Ammerdorffer A, Labastida F, Pereira T, Ramm GA, Engwerda CR. 2011. High Parasite Burdens Cause Liver Damage in Mice following *Plasmodium berghei* ANKA Infection Independently of CD8+ T Cell-Mediated. *Infect Immun* 79:1882-1888. <http://dx.doi.org/10.1128/IAI.01210-10>
- Helegbe GK, Yanagi T, Senba M, Huy NT, Shuaibu MN, Yamazaki A, Kikuchi M, Yasunami M, Hirayama, K. 2011. Histopathological studies in two strains of semi-immune mice infected with *Plasmodium berghei* ANKA after chronic exposure. *Parasitol Res* 108:807-814. <http://dx.doi.org/10.1007/s00436-010-2121-6>
- Hoffman BU, Chattopadhyay R. 2008. *Plasmodium falciparum*: Effect of radiation on levels of gene transcripts in sporozoites. *Exp Parasitol* 118:247-252. <http://dx.doi.org/10.1016/j.exppara.2007.08.014>
- Kramer B, Grobusch MP, Suttorp N, Neukammer J, Rinneberg H. 2001. Relative frequency of malaria pigment-carrying monocytes of nonimmune and semi-immune patients from flow cytometric depolarized side scatter. *Cytometry* 45:133-140. [http://dx.doi.org/10.1002/1097-0320\(20011001\)45:2<133::AID-CYTO1155>3.0.CO;2-K](http://dx.doi.org/10.1002/1097-0320(20011001)45:2<133::AID-CYTO1155>3.0.CO;2-K)
- Lawrence C, Olson JA. 1986. Birefringent hemozoin identifies malaria. *Am J Clin Pathol* 86:360-363.
- Luke TC, Hoffman SL. 2003. Rationale and plans for developing a non-replicating, metabolically active, radiation-attenuated *Plasmodium falciparum* sporozoite vaccine. *J Exp Biol* 206:3803-3808. <http://dx.doi.org/10.1242/jeb.00644>
- Maude RJ, Buapetch W, Silamat K. 2009. Short Report: A Simplified, Low-Cost Method for Polarized Light Microscopy. *Am J Trop Med Hyg* 81:782-783. <http://dx.doi.org/10.4269/ajtmh.2009.09-0383>
- Mendelow BV, Lyons C, Nhlangothi P, Tana M, Munster M, Wypkema E, Liebowitz L, Marshall L, Scott S, Coetzer TL. 1999. Automated malaria detection by depolarization of laserlight. *Br J Haematol* 104:499-503. <http://dx.doi.org/10.1046/j.1365-2141.1999.01199.x>
- Nurhayati S. 2011. Propagation of Irradiated *Plasmodium berghei* at High Dose Rate in Mice (*Mus musculus*). Proceeding of Scientific Presentation on Safety, Health and Environmental VII, Jakarta.
- Nussenzweig RS, Vanderberg J, Most H, Orton C. 1967. Protective immunity produced by the injection of X-irradiated sporozoites of *Plasmodium berghei*. *Nature* 216:160-162. <http://dx.doi.org/10.1038/216160a0>
- Ramadhani D, Rahardjo T, Nurhayati S. 2012. Automated Measurement of Haemozoin (Malarial Pigment) Area in Liver Histology Using ImageJ 1.6. Proceeding of 6th Electrical Power, Electronics Communication, Control and Informatics Seminar (EECCIS), Malang.
- Rieckmann KH, Beaudoin RL, Cassells JS, Sell DW. 1979. Use of attenuated sporozoites in the immunization of human volunteers against falciparum malaria. *Bull World Health Organ* 57:261-265.
- Romagosa C, Menendez C, Ismail MR, Quintó L, Ferrer B, Alonso PL, Ordi J. 2004. Polarisation microscopy increases the sensitivity of hemozoin and *Plasmodium* detection in the histological assessment of placental malaria. *Acta Trop* 90:277-284. <http://dx.doi.org/10.1016/j.actatropica.2004.02.003>

- Shittu I, Emmanuel A, Nok AJ. 2011. Antimalaria Effect of the Ethanolic Stem Bark Extracts of *Ficus platyphylla* Del. *Journal of Parasitology Research* 2011:1-5. <http://dx.doi.org/10.1155/2011/618209>
- Syaifudin M, Tetriana D, Darlina, Nurhayati S. 2011. The Feasibility of Gamma Irradiation for Developing Malaria Vaccine. *AIJ* 37:91-101.
- Tetriana D, Darlina. 2007. Determination of Irradiation Dose to Attenuate *Plasmodium berghei* in Erythrocytic Stage. Proceedings of the Meeting and Scientific Presentations functional development of nuclear technology I, Jakarta.