

SHORT COMMUNICATION

Anti Lithiasis Activity of Avocado (*Persea americana* Mill) Leaves Extract in White Male Rats

IETJE WIENTARSIH*, RINI MADYASTUTI, BAYU FEBRAM PRASETYO, ANGGARA ALDOBRATA

*Department of Clinic, Reproduction, and Pathology, Faculty of Veterinary Medicine,
Bogor Agricultural University, Darmaga Campus, Bogor 16680, Indonesia*

Received February 17, 2011/Accepted February 24, 2012

In Indonesia, avocado leaves have been used as traditional medicines for diureticum to cure urolithiasis. This research was to determine anti lithiasis activity of avocado leaves (*Persea americana* Mill) extract on white male rats nephrolithiasis model induced by ethylene glycol. Ethanol extraction method was used to get extract of avogadro leaves. Twenty adult male white rats were divided into 4 different induction treatments i.e. aquadest, ethylene glycol 0.75% and ammonium chloride 2%, and extract of avocado leaves with different levels of 100 and 300 mg/kg bw respectively. Their body weight was measured daily to determine their growth ratio. And at the end of the trial, the kidney was analyzed its calcium level and inhibitory activity to formation of calcium oxalate crystals. The results showed that the amount of calcium level in the kidney of rats treated with extract of avogadro leaves was significantly decreased than that of rats treated with ethylene glycol 0.75% and ammonium chloride 2% ($P < 0.05$). The extract avocado leaves as a herbal remedy can be recommended as a phytotherapeutic agent especially for preventive action for urolithiasis diseases.

Key words: *Persea americana* Mill, anti lithiasis, kidney stone, ethylene glycol

INTRODUCTION

Nephrolithiasis is the third prevalent disorder in the urinary system. Approximately, 80% of these nephrolith are composed of calcium oxalate (CaOx). Nephrolith is a solid particle like gravels that exists in every part of urinary system. It is formed by excessive salt in the blood-stream and then it crystallizes in the kidney. The size and shape of the gravel is vary, from the very tiny particle that flowing undetectably through the blood stream till the gravel's size. However, even the tiniest gravel or stone is able to cause the great pain when it moves out of the kidney. Minor bleeding can be seen when the gravel causes the wound inside urinary system. In most cases kidney stone are source of discomfort and inconvenience, progressive lost of renal function can occur after repeated episodes of stone disease (Park & Pearle 2007).

Chemical medicines are used only to prevent growing stones to be bigger and helping excretion of kidney stones (nephrolith) spontaneously. Diuretics are commonly used in the treatment of hypertension and other disorders associated with edema and heart disease.

Apparently avocado leaves are one natural ingredient that can be used as a traditional medicine. The leaves have been used as a diuretic, anti-inflammation, anti-hypertension, hypoglycaemia, diarrhea, sore throat, and

bleeding (Brai *et al.* 2007). However, people only notice the good effect of avocado leaves is based on empirical evidence. Therefore, this study determined the effect of avocado leaves extract on lithiasis.

MATERIALS AND METHODS

Persea americana Mill. leaves were collected from Research Institute for Herbs and Spicy Bogor Indonesia. *Persea americana* powder was macerated with ethanol 70% for 48 h and the extract was concentrated to get a semisolid extract using a rotary evaporator. Temperature of the evaporator was maintained below 60 °C. The *P. americana* (avocado) leave extract was evaluated for presence of various phytoconstituents by performing different qualitative chemical tests.

Twenty male *Sprague Dawley* (200-250 g) were used in this study. Experimental Animals were acclimated for seven days for adaptation. Animals were fed *ad libitum*. Animals were divided randomly into 4 groups (n = 5) and were treated as follow: group A were untreated and served as normal control, group B, C, and D were induced with 0.75% ethylene glycol and 2% ammonium chloride in drinking water *ad libitum* for ten days. Group C and D were fed orally with ethanol extract *P. americana* solution with different levels (100 and 300 mg/kg bw).

After ten days experiment period, the animals were anesthetized by ether and the kidney samples were taken for analysis. The left kidney was dried in oven at 100 °C

*Corresponding author. Phone/Fax: +62-251-8623940,
E-mail: wien_tje@yahoo.com

for 24 h, then weighed and minced in a beaker glass containing 7 ml of 0.5 N nitric acid. The mixture was heated until the liquid became transparant. Calsium concentration was determined by atomic absorption spectroscopy method.

RESULTS

Phytochemical Assay. *Persea Americana* (Avocado) leaves powder which was macerated with ethanol and then evaporated produced 34% yield extract. The result of phytochemical assay showed that extract of avocado leaves contains alkaloid, tannin, saponin, tritherphenoid, and flavonoid (Table 1).

Body and Kidney Weight, and Their Ratio. There was body weight increasing until eighth day of experiment in

Table 1. Phytochemical assay of *Persea americana* (avogadro) leaf extract of ethanol extraction

Compound	Result
Flavonoid	++++
Alkaloid	++
Tannin	+
Saponin	+
Tritherphenoid	+

+ = detected.

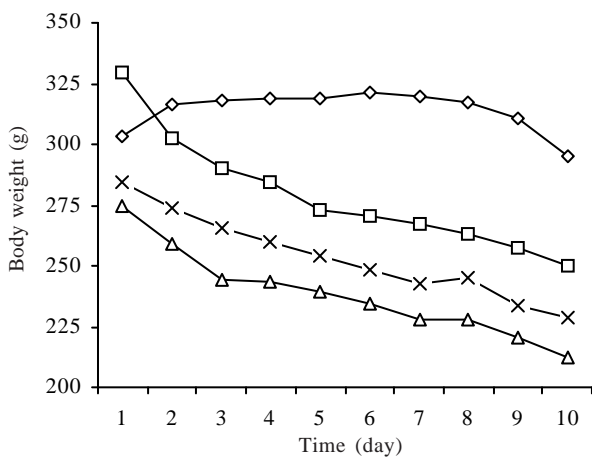


Figure 1. Body weight of adult male white rats induced with four different treatments in 10 days of experimental period. ◇ = normal control, □ = positive control, △ = treated dose 100 mg/kg bw, × = treated dose 300 mg/kg bw.

the control. On the other hand there was significant body weight decreasing ($P < 0.05$) on the rats treated with extract Avogadro leaves 100 and 300 mg/kg bw compared to that of treated with 0.75% ethylene glycol and 2% ammonium chloride (Figure 1 and Table 2).

Average body and kidney weight and its ratio of control was 314.98, 1.12, and 0.71 g, respectively. Meanwhile on the rats treated with 0.75% ethylene glycol and 2% ammonium chloride, the body weight, kidney weight and ratio was 278.8, 1.12, and 0.77 g, respectively. Average of body weight of the rats treated with extract of Avogadro leaves 100 and 300 mg/kg bw was 238.45 and 253.73 g, respectively. And the kidney weight was 0.86 and 0.97 g respectively, and the ratio was 0.72 and 0.76 respectively.

There was a decreasing in ratio of body and kidney. However, statistical analysis showed that there was no significant effect ($P > 0.05$) on the creasing of body and kidney weight ratio. Compared to that of treated with 0.75% ethylene glycol and 2% ammonium chloride, the differences of decreasing of body weight on rats treated with extract of Avogadro leaves 100 mg/kg bw was up to 7%, while on rats treated with extract of Avogadro leaves 300 mg/kg bw was 1%.

Calcium Concentration in the Rat Kidney. Statistical analysis of calcium concentration in kidney renal showed that there was significant different ($P < 0.05$) on treatments extract of Avogadro leaves 100 and 300 mg/kg bw, compared to positive control of 0.75% ethylene glycol and 2% ammonium chloride (Table 3). The data showed that extract of avocado leaves could decrease concentration of calcium in the kidney.

DISCUSSION

Extraction process in general used 70% ethanol to extract active compounds such as polyphenols, flavonoids, tannin, and alkaloids. Ethanol's polarity is less than water's polarity, therefore degrading cell walls and seeds that have unpolar character will be efficient (Lapomik et al. 2005).

Phytochemical assay of extract of avocado leaves was conducted to observe the type of secondary metabolite compounds of extract contents. The result showed that the presence of flavonoid is much higher than other

Table 2. Average of body and kidney weight and their ratio of adult male white rats induced with four different treatments

Weight	A	B	C	D
Body (g)	314.98 ± 7.97 ^c	278.80 ± 23.63 ^b	238.45 ± 18.47 ^a	253.72 ± 17.64 ^a
Kidney (g)	1.12 ± 0.08	1.07 ± 0.24	0.86 ± 0.26	0.97 ± 0.26
Ratio	0.71	0.77	0.72	0.76

Different superscript indicates that is significantly different ($P < 0.05$, n = 5). A = normal control, B = positive control, C = treated dose 100 mg/kg bw, D = treated dose 300 mg/kg bw.

Tabel 3. Renal calcium concentration

	A	B	C	D
Ca concentration (mg)	0.075 ± 0.013 ^b	0.139 ± 0.079 ^a	0.060 ± 0.012 ^b	0.067 ± 0.009 ^b

Different superscript indicates that is significantly different ($P < 0.05$, n = 5). A = normal control, B = positive control, C = treated dose 100 mg/kg bw, D = treated dose 300 mg/kg bw.

compounds such as alkaloid, tannin, saponin, and triterpenoid (Table 1). According to Wientarsih *et al.* (2000), avocado's leaves contain saponin, alkaloids, flavonoids, polyphenols, and quersetin. According to Spigno and Favari (2007), antioxidant activity was higher when the extract contains more flavonoids. Flavonoids are polyphenolic compounds which widespread in the plant and have diverse pharmacological effects such as anticancer, antioxidant, antiaging and antibacteria (Xu *et al.* 2007). According to Singh (2005), derivate of flavonoid can repair the damage of the kidney by capacity of antioxidant activity and as radical scavenger. The effect of avocado's leaf extract in the both treatment significantly decreased calcium level in the kidney compared to the positive control (0.75% ethylene glycol and 2% ammonium chloride treatment) because of much higher flavonoid content in the extract. According to Fouada *et al.* (2006), flavonoid property of extract of avocado's leaves (with ethanol extraction) can prevent attachment of CaOx crystals and stop the further process in the formation of kidney stones. Flavonoid can prevent adhesion of crystal calcium oxalate by scavenging effects in prevent injury by free radical and resulting more stable radical. In other words, flavonoids stabilize the reactive oxygen species by hydroxyl group which has high reactivity according to the following equation: Flavonoid (OH) + R· → Flavonoid (O·) + RH (Nijveldt *et al.* 2001).

Ethylene glycol (EG), as a nephrotoxic agent, is commonly used as an experimental regiment to induce animal models of calcium oxalate nephrolithiasis. Therefore, EG was used in this experiment to make hyperoxaluria condition.

Hyperoxaluria is a major risk factor of calcium oxalate disease and leads to increasing of calcium oxalate supersaturation and calcium oxalate stone formation. Exposure to oxalate has been shown to be toxic to renal epithelial cells, which results in lipid peroxidation mediated by free radicals. Oxalate toxicity is mediated, in part, by activation of lipid signaling pathways that produce arachidonic acid, lysophospholipids, and ceramide. These lipids, in turn, are able to disrupt mitochondrial function by increasing production of reactive oxygen intermediates (ROI), decreasing mitochondrial membrane potential, and increasing mitochondrial permeability (Meimaridou *et al.* 2006).

Effect of the avocado's leaf extract in different levels in animals could decrease ratio of body and kidney weight. Nephrolithiasis increase kidney weight due to inflammatory reactions which has high mineral content in the kidney. Cruzan *et al.* (2004) stated that white rats body weight were decreased due to the high doses of ethylene glycol poisoning as well as the increasing of kidney weight and kidney weight ratio relative to body weight. Increasing of kidney's weight was due to inflammation process and mineral content. In this research, the activity of flavonoid as anti-inflammation made the ratio of kidney's weight decreased. The role of flavonoid in preventing formation of crystal calcium oxalate due to the anti-inflammatory

action through inhibition of leukotriene synthesis, prevention of histamine release (Kheir eldin *et al.* 2008) and inhibition of neutrophil degranulation.

On the measurement of calcium level in the kidney (Table 3), The calcium level of rat kidney in Avocado leaf extract treatment was lower than that of the positive control. The extract of avocado's leaves could decrease calcium level in the kidney and therefore showed inhibition of calcium oxalate nephrolith. According to Khan *et al.* (2000) calcium oxalate crystal and high oxalate levels in the nephrons can damage the epithelial cells and consequently, the cell may produce some products as well as free radical inducing heterogenous crystal nucleation and cause aggregation of crystals.

Crystal formation and retention are critical events for the formation of kidney stones. Oxalate and calcium oxalate (CaOx) crystals are injurious to renal epithelium. Membranes of injured cells promote crystal adherence and retention.

Ratio of kidney and body weight depends on the size and thickness of the kidney itself (Baker *et al.* 1979). Kidney's abnormality in the positive control treatment is caused by inflammation and mineral deposit condition. The ratio of positive control was 0.77 and the ratio of the Avocado leaf extract 100 mg/kg bw was 0.72, anti-inflammatory and anti oxidant activity of avocado's leaf extract could decrease ratio of kidney and body weight (Table 2).

In conclusion, extract of avocado's leaves with ethanol extraction is an efficient agent to inhibit formation of calcium oxalate crystal in the rats' kidney. The extract of avocado's leaves is potential natural antioxidant and anti inflammation compounds that able to prevent formation of calcium oxalate crystal by interfering process of epithelial cell damage.

ACKNOWLEDGEMENT

This study was supported by Directorate of Higher Education Competency Grant number 0154/023-04.2/XII/2009 to Ietje Wientarsih.

REFERENCES

- Baker HJ, Lindsey JR, Weisbroth SH. 1979. The Laboratory Rat: Biology and Disease. Vol 1. New York: Acad Pr Inc.
- Brai BIC, Odetola AA, Agomo PU. 2007. Effects of persea americana leaf extracts on body weight and liver lipid in rats fed hyperlipidaemic diet. *Afr J Biotechnol* 6:1007-1011.
- Cruzan G, Corley RA, Hard GC, Mertens JJWM, McMartin KE, Snellings WM, Gingell R, Deyo JA. 2004. Subchronic toxicity of ethylene glycol in wistar and F-344 rats related to metabolism and clearance of metabolites. *Toxicol Sci* 81:502-511. <http://dx.doi.org/10.1093/toxsci/kfh206>
- Eldin AAK, Shaheen AA, Elgawad HMA, Shehata NI. 2008. Protective effect of taurine and quercetin against renal dysfunction associated with the combined use of gentamycin and diclofenac. *Indian J Biochem Biophys* 45:332-340.
- Fouad A, Yamina S, Addi NM, Mohammed B, Abdlekrim R. 2006. *In vitro* and *in vivo* antilithiasic effect of saponin rich fraction isolated from herniaria hirsuta. *J Bras Nefrol* 28:199-203.

- Khan SR, Thamilselvan S. 2000. Nephrolithiasis: a consequence of renal epithelial cell exposure to oxalate and calcium oxalate crystal. *Mol Urol* 4:305-312.
- Lapornik B, Mirko P, Wondra AG. 2005. Comparison of extracts prepared from plant by products using different solvents and extraction time. *J Food Eng* 71:214-222. <http://dx.doi.org/10.1016/j.jfoodeng.2004.10.036>
- Meimaridou E, Lobos E, Hothersall S. 2006. Renal oxidative vulnerability due to changes in mitochondrial-glutathione and energy homeostasis in a rat model of calcium oxalate urolithiasis. *Am J Physiol Renal Physiol* 291:F731-F740. <http://dx.doi.org/10.1152/ajprenal.00024.2006>
- Nijveldt R, Van Nood E, Van Hoorn DEC, Boelens PG, Van Norren K, Van Leeuwen PAM. 2001. Flavonoids: a review of probable mechanisms of action and potential applications. *Am J Clin Nutr* 74:418-425.
- Park S, Pearle MS. 2007. Pathophysiology and management of calcium stones. *Urol Clin Am* 34:323-324. <http://dx.doi.org/10.1016/j.ucl.2007.04.009>
- Singh D, Chander V, Chopra K. 2005. Protective effect of catechin on ischemia reperfusion induced renal injury in rats. *Pharmacol Rep* 57:70-76.
- Spigno G, Favari DMD. 2007. Antioxidants from grape stalks and marc: influence of extraction procedure on yield, purity, and antioxidant power of the extracts. *J Food Eng* 78:793-801. <http://dx.doi.org/10.1016/j.jfoodeng.2005.11.020>
- Wientarsih I. 2008. Aktivitas Ekstrak Etanol Daun Alpukat (*Persea americana gaertn*) Terhadap Batu Ginjal Buatan dan Diuretik pada Tikus Putih. Bogor: Institut Pertanian Bogor.
- Xu Yc, Leung SWS, Yeung DKY, Hu LH, Chen GH, Che CM, Man RYK. 2007. Structure activity relationships of flavonoids for vascular relaxation in porcine coronary artery. *Phytochemistry* 68:1197-1188.