

## X-RAY RADIOGRAPHIC STUDY OF $\beta$ -TRICALCIUM PHOSPHATE BIOCERAMICS AS A TOOTH FILLER

N. A. Nuzulia<sup>1</sup>, Gunanti<sup>2</sup>, S. Agungpriyono<sup>2</sup>, K. Dahlan<sup>1\*</sup>

<sup>1</sup>Department of Physics, Faculty of Mathematics and Natural Sciences, Bogor Agricultural University (IPB), Bogor 16680, Indonesia

<sup>2</sup>Faculty of Veterinary Medicine, Bogor Agricultural University, Indonesia

\*kiagusd@yahoo.com

### ABSTRACT

Preservation of alveolar bone following tooth extraction is an important step in dental practices before dental implant placement. This study reported the use of  $\beta$ -TCP as a tooth filler to maintain the desired alveolar ridge dimension and stimulate the bone healing processes in the area of tooth loss. The  $\beta$ -TCP used in this study is pure  $\beta$ -TCP made of chicken eggshells. The corresponding  $\beta$ -TCP was mixed with chitosan 2% to get  $\beta$ -TCP pellet for biocompatibility testing. Biocompatibility testing of  $\beta$ -TCP on lower incisor was performed in rabbits and sheep as animal model. Animal models (rabbits and sheep) implanted with  $\beta$ -TCP demonstrated the expected results. The x-ray radiograph of rabbit's jaw showed the formation of complete tooth and tooth growth at D+30 PO on alveolar socket. Moreover, the x-ray radiographs of sheep's jaw indicated no change on mesiodistal of the edentulous area. It was obvious that the corresponding  $\beta$ -TCP could accelerate the formation of complete tooth on rabbit, minimize the postextraction bone loss and maintain the alveolar ridge dimension on sheep.

Keywords: Alveolar socket,  $\beta$ -TCP bioceramics, x-ray radiographs

### ABSTRAK

Preservasi tulang alveolar setelah ekstraksi gigi merupakan langkah penting dalam praktek gigi sebelum pemasangan implan gigi. Penggunaan  $\beta$ -TCP sebagai tooth filler dalam penelitian ini bertujuan untuk mempertahankan dimensi alveolar ridge yang diinginkan dan merangsang proses penyembuhan tulang di daerah hilangnya gigi.  $\beta$ -TCP yang digunakan dalam penelitian ini adalah  $\beta$ -TCP murni yang terbuat dari cangkang telur ayam.  $\beta$ -TCP dalam bentuk pelet digunakan untuk pengujian biokompatibilitas dengan cara mencampur  $\beta$ -TCP yang diperoleh dengan kitosan 2%. Pengujian biokompatibilitas  $\beta$ -TCP pada gigi seri bawah dilakukan pada kelinci dan domba sebagai hewan model. Hewan model (kelinci dan domba) yang diisi dengan  $\beta$ -TCP menunjukkan hasil yang diharapkan. Radiograf sinar-x rahang kelinci menunjukkan pembentukan gigi sempurna dan pertumbuhan gigi pada alveolar socket di hari ke-30 post operasi. Selain itu, radiografi sinar-x rahang domba menunjukkan tidak adanya perubahan jarak mesiodistal di edentulous area. Hasil penelitian menunjukkan bahwa  $\beta$ -TCP mampu mempercepat pembentukan gigi sempurna pada kelinci, meminimalis kehilangan tulang postextraction dan menjaga dimensi alveolar ridge pada domba.

Kata kunci: Alveolar socket, biokeramik  $\beta$ -TCP, radiografi sinar-x.

## INTRODUCTION

Alveolar bone resorption is a physiological process that occurs after a tooth extraction. The rate of alveolar bone resorption is fairly high as a reduction of about millimeters happens in the first 6 months of the healing process and two-thirds of reduction occurs in the first 3 months.<sup>1,2</sup> It is observed that over 12 months the reduction is about 50% in both horizontal and vertical directions.<sup>2</sup> A very progressive bone resorption is able to reduce the dimensions of the socket and lead to the bone atrophy and cause difficulty on implant or prostheses placement. Therefore, preservations of bone volume in the area of tooth loss are necessary to maintain the dimensions of the alveolar ridge. The use of filling biomaterials is one way to preserve the adequate bone volume that commonly used by clinicians. Biomaterials have some advantages compared to the gold standard (autogenous procedure) due to their ability to eliminate problems of donor scarcity, supply limitation, pathogen transfer, and immune rejection.<sup>3</sup>

$\beta$ -Tricalcium Phosphate ( $\beta$ -TCP) is a promising biomaterial as its bioactive properties might cause a positive reaction after implantation such as stimulating bone tissue formation and promoting the regeneration of bones.<sup>2,4,5</sup> In addition,  $\beta$ -TCP has also been shown to exhibit biocompatibility, osteoconductivity, and biodegradability properties.<sup>2,4,5,7,8</sup> Previous study shows that this material marked osteoconductivity and bioabsorbability after implantation in human bone.<sup>9</sup> Other studies also show that  $\beta$ -TCP can prevent alveolar crest resorption following tooth extraction.<sup>2,4,10</sup>

This study aimed to observe the use of  $\beta$ -TCP bioceramics as a tooth filler by using rabbits and sheeps as animal models. Rabbits are animal model for observing the phenomenon of tooth growth that could be applied for cases of premature tooth loss while sheep are animal model for postextraction preservation of permanent tooth loss.

## MATERIALS AND METHODS

The materials used in this research are  $\beta$ -TCP bioceramics formed from chicken's eggshells, chitosan, and aquabidest. While materials used for biocompatibility test are rabbits and sheep as animal models, minor surgery sets, dental surgery tools, anesthetic materials, surgery room for aseptical insertion, and x-ray radiography sets.

$\beta$ -TCP bioceramics used for biocompatibility test was in the form of pellet. The corresponding  $\beta$ -TCP powder was mixed with chitosan 2% mechanically. The following processes were molding in form of pellet with 2 mm in diameter for rabbits and 6 mm for sheep then the pellets were heated in incubator at 50°C for 6 hours.

Biocompatibility test of  $\beta$ -TCP bioceramics as a tooth filler was performed by using rabbits and sheep as animal models. There are two rabbits used with 2.5 kg body weight and three 1 year old sheep. All experiments were conducted along the institutional guidelines for the care and use of laboratory animals. Prior to surgery, the animal models were

observed closely for a week in order to check their health status. They were maintained under identical environment, management and standard diet with *ad libitum* supply of drinking water. Then, surgery was done on the lower incisor. Before surgery, rabbits and sheep were anaesthetized by injection of ketamine and xylazin 2%. Under aseptical conditions, the lower incisor was extracted and immediately after tooth extraction, the alveolar socket was filled with synthesized  $\beta$ -TCP bioceramics that were sterilized initially by exposure to ultraviolet light. As control requirement, other rabbit's and sheep's lower incisor were extracted in the same manner and unfilled with any tooth filler. Each surgery was performed under same veterinary surgeon. Then, the rabbits and sheep were housed under a climate-controlled environment in stall of animal used of FVM Bogor Agricultural University.

The alveolar sockets that filled with  $\beta$ -TCP tooth filler and unfilled with any tooth filler were monitored using a set of x-ray radiographic apparatus in day+0 pre operation, D+0 post operation (PO), D+7 PO and D+30 PO for observing the tooth growth on rabbits and alveolar bone healing on sheep. Then, the rabbits and sheep were euthanized on D+30 PO for macroscopic evaluation.

## RESULTS AND DISCUSSION

The purity of  $\beta$ -TCP bioceramics based on chicken's eggshells was proven by x-ray diffraction (XRD) profile as shown in Figure 1. The three important highest peaks pattern is observed on  $2\theta = 31.06^\circ$ ,  $34.42^\circ$ , and  $27.84^\circ$  which are completely similar to the peaks pattern of  $\beta$ -TCP database number 09-0169.

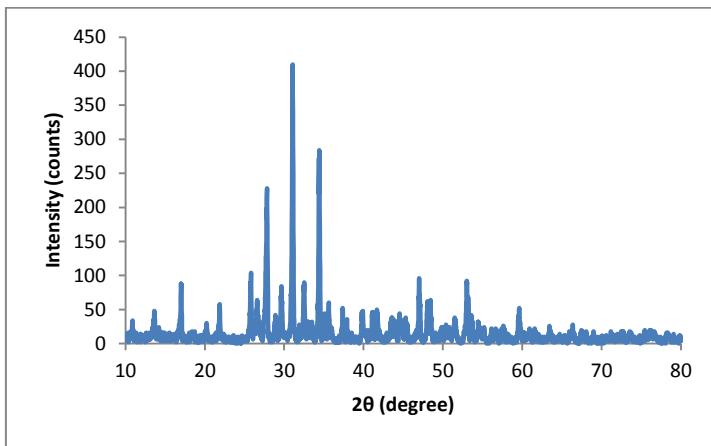


Figure 1 X-ray diffraction (XRD) profile of as-received  $\beta$ -TCP bioceramics.

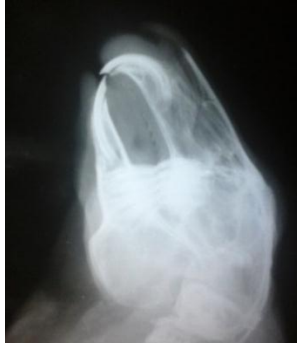

Figure 2 The radiograph of rabbit's jaw pre-operation.

Biocompatibility testing of  $\beta$ -TCP as tooth filler was performed on rabbits to observe the tooth growth after tooth extraction. The radiograph of rabbit's jaw pre operation is shown in Figure 2 and the radiograph of rabbit's jaw as control and treatment is shown in Figure 3 and 4. Based on the radiograph in Figure 3 and 4, these results show a tooth growth on rabbits at D+30 PO that was demonstrated by the presence of margin and high opacity on an extracted tooth area. It was clear that alveolar socket of lower incisors rabbit on D+0 PO (Figure 3a) had low opacity and then increase on D+7 PO as shown in Figure 3b. Increasing of alveolar socket opacity indicates the formation of tooth germ precursor tissue. It was also observed that in Figure 3b there was a tooth growth on upper incisors rabbit. It might because rabbits are a lagomorpha with all teeth continually growing. Moreover, the radiograph of alveolar socket's rabbit on D+30 PO (Figure 3c) demonstrated the formation of new teeth which was shown by increasing opacity with apparent margin. Nevertheless, the empty space around alveolar socket of lower incisors obviously indicated the incomplete tooth formation. In the meantime, the macroscopic result of rabbit's mandibular at D+30 harvesting as shown in Figure 5 was in accordance with the radiograph result of alveolar socket at D+30 PO. It is clear that there was unerupted tooth on D+30 harvesting due to no appearance of tooth on gums surface.

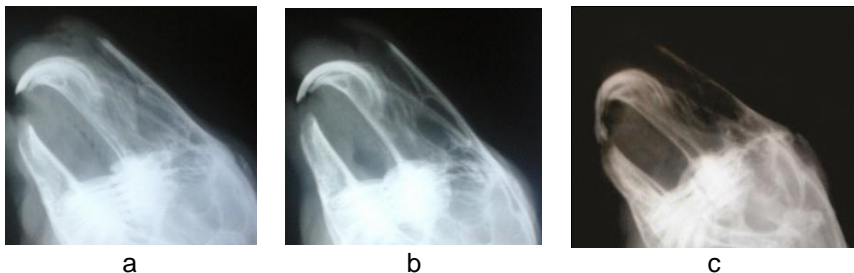

Figure 3 The radiograph of rabbit (control) at (a) day+0 post operation (b) day+7 post operation (c) day+30 post operation.

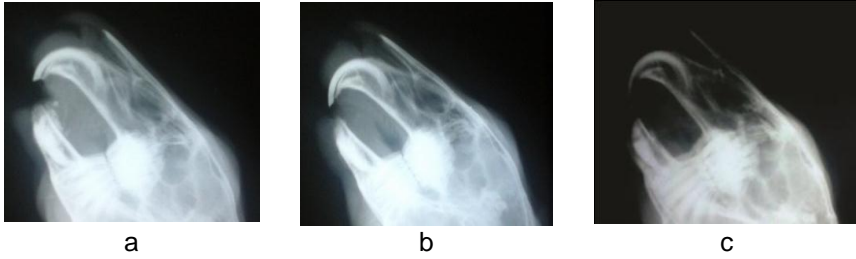

Figure 4 The radiograph of rabbit (treatment) at (a) day+0 post operation (b) day+7 post operation (c) day+30 post operation.

On the contrary, the radiograph of alveolar socket filled with  $\beta$ -TCP as shown in Figure 4 demonstrated the tooth growth on rabbit. As seen in Figure 4a, the alveolar socket was filled with  $\beta$ -TCP and there was higher opacity than one in control at D+0 PO, which might be caused by the similar inorganic component of  $\beta$ -TCP with bone. At the same time, there was jaw bone fracture during tooth extraction shown by unclear margin that is different with the origin. Figure 4b clearly shows resorption of  $\beta$ -TCP by the body fluids that are indicated by volume decreasing of  $\beta$ -TCP pellet in alveolar socket. In addition, there was a tooth growth of upper incisors rabbit at D+7 as well as at the control. However, there were differences on rabbits alveolar socket filled with  $\beta$ -TCP at D+30 PO. It was clear that  $\beta$ -TCP had been resorbed and could accelerate the formation of complete tooth shown from its radiograph with clear margin at Figure 4c. In the meantime, jaw bone healing process was observed indicated by bone margin which was similar with that of pre-operation bone margin. Furthermore, this result was supported by macroscopic result at D+30 PO as seen in Figure 5 that indicates the complete tooth formation of rabbits lower incisors due to the erupted tooth of 15 mm. it demonstrated a rapid growth of rabbits lower incisors and relevant to the other studies that reported lower incisors growth is approximately 2-3 mm per week.<sup>11,12</sup>

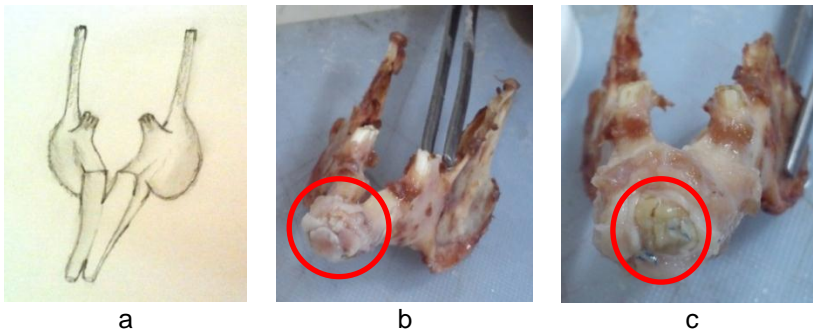


Figure 5 Macroscopic results of rabbit's mandible at Day+30 harvesting (a) sketch of rabbit's mandible (b) control (c) treatment.

In contrast with control, the upper incisors growth of rabbit was shorter than that of control. It might be caused by the presence of erupted tooth and makes slower growth on the rabbit upper incisors. It was obvious that  $\beta$ -TCP

could accelerate the formation of complete tooth and stimulate the tooth growth. In short, it could be applied clinically in case of premature tooth loss that commonly happen in children.

On the other hand, biocompatibility testing was done in sheep to observe the alveolar bone healing process by resubstituting process of the corresponding  $\beta$ -TCP. As a requirement, sheep jaw's radiograph pre-operation was done as shown in Figure 6. The radiograph of control (sheep's alveolar socket that unfilled with  $\beta$ -TCP) in Figure 7 demonstrate the alveolar bone resorption that could be seen from the narrower mesiodistal of edentulous area along the observing time. As seen in Figure 7a, there was a larger distance of the alveolar ridge after tooth extraction with low opacity due to the unfilled socket. The dimension of the alveolar ridge had changed at D+7 PO (Figure 7b) and clearly followed by significant change at D+30 PO (Figure 7c). This result was clearly related to the macroscopic result at D+30 harvesting day in Figure 9a. It exhibited the faster resorption of alveolar bone in control shown by no space in the edentulous area.

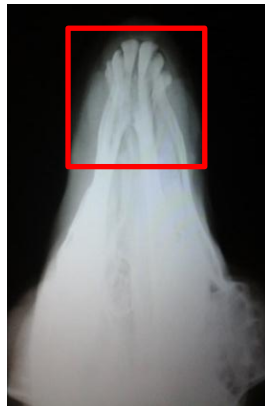

Figure 6 The radiograph of sheep 's jaw pre-operation.

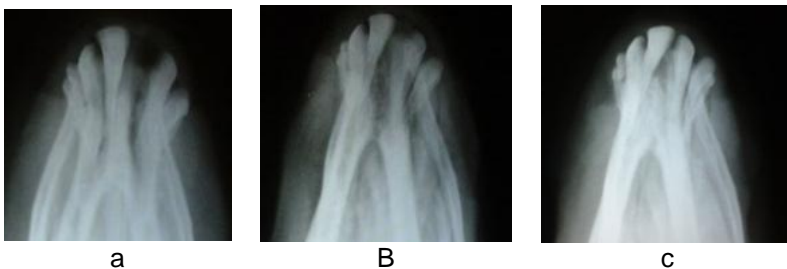

Figure 7 The radiograph of sheep (control) at (a) day+0 post operation (b) day+7 post operation (c) day+30 post operation.

In contrast, sheep's alveolar socket that filled with the corresponding  $\beta$ -TCP showed the expected goal. Figure 8 indicates resubstituting processes of  $\beta$ -TCP and shows preservation phenomena on the alveolar ridge. It was obvious from mesiodistal of the edentulous area that it remains

in the same width. High opacity on D+0 PO as shown in Figure 8a demonstrated the alveolar socket filled with  $\beta$ -TCP after tooth extraction. The same alveolar ridge width was observed at D+7 PO with  $\beta$ -TCP resorption due to the decreasing of opacity on the alveolar socket (Figure 8b). There was a little change on alveolar ridge at D+30 PO as shown in Figure 8c. Macroscopic result of D+30 harvesting day confirms the bone healing process on postextraction socket as shown in Figure 9b. The detailed mesiodistal of the edentulous area is shown in Table 1. It is worth to note that  $\beta$ -TCP as a tooth filler could stimulate the alveolar bone healing process and maintain the desired alveolar ridge. This preservation could be done before prostheses or implant placement.

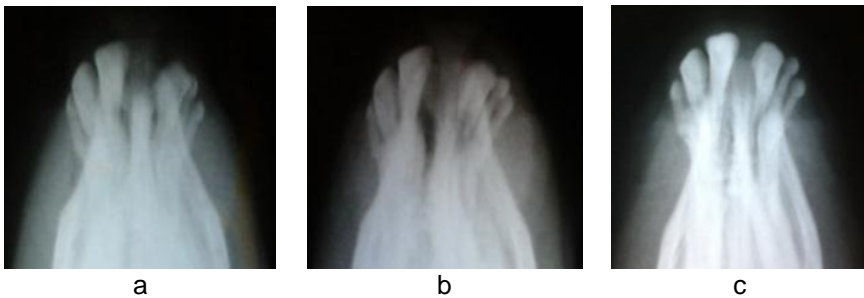

Figure 8 The radiograph of sheep (treatment) at (a) day+0 post operation (b) day+7 post operation (c) day+30 post operation.

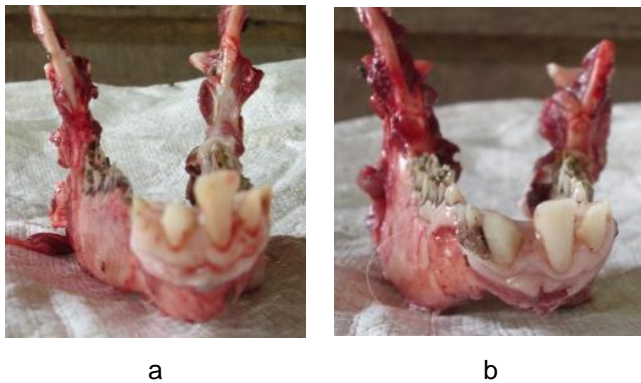


Figure 9 Macroscopic results of sheep's mandible at Day+30 harvesting (a) control (b) treatment.

Table 1 Mesiodistal of the edentulous area

Sheep's sample	Mesiodistal at Day+0 post operation (mm)	Mesiodistal at D+7 post operation (mm)	Mesiodistal at D+30 post operation (mm)
Control	6	5	1
Treatment	6	6	5

## CONCLUSION

The use of  $\beta$ -TCP bioceramics as a tooth filler on postextraction preservation of alveolar socket shows a promising challenge in dental practices. The radiograph of rabbit's alveolar socket filled with  $\beta$ -TCP indicates the formation of complete tooth and tooth growth proved by the erupted tooth on macroscopic result. The alveolar bone healing process is obviously observed on sheep shown by mesiodistal of the edentulous area that remains same alveolar ridge width.

## REFERENCES

1. Kokovic V and Todorovic L. Preimplantation filling of tooth socket with  $\beta$ -tricalcium phosphate/poly(lactic)/poly(glycolic) acid ( $\beta$ -TCP/PLGA) root analogue: clinical and histological analysis in a patient. *Vojnosanitetski Pregled*. 2011; 68 (4): 366-371.
2. Brkovic BMB, Prasad HS, Konandreas G, Milan R, Antunovic D, Sándor GBK, Rohrer MD. Simple preservation of a maxillary extraction socket using beta-tricalcium phosphate with type I collagen: preliminary clinical and histomorphometric observations. *JCDA*. 2008; 74 (6): 523-528.
3. Costa HS *et al*. Morphological, mechanical, and biocompatibility characterization of macroporous alumina scaffolds coated with calcium phosphate/PVA. *Material Science*. 2008; 43: 510-524.
4. Horowitz RA, Mazor Z, Foitzik C, Prasad H, Rohrer M, Palti A.  $\beta$ -tricalcium phosphate as bone substitute material: properties and clinical applications. *The International Journal of Dental Implants & Biomaterials: Titanium*. 2009; 1 (2): 2-11.
5. Padaropoulos L, Veis AA, Papadimitriou S, Alexandridis C, Kalyvas D. Bone regeneration using  $\beta$ -tricalcium phosphate in a calcium sulfate matrix. *Journal of Oral Implantology*. 2009; 35 (1): 28-36.
6. Oi Yosei. Beta-tricalcium phosphate and basic fibroblast growth factor combination enhances periodontal regeneration in intrabony defects in dogs. *Dental Materials Journal*. 2009; 28 (2): 162-169.
7. Ain RN, Sopyan I, Ramesh S. Preparation of Biphasic calcium phosphate ceramics powders and conversion to porous bodies. *ICCBT*. 2008; 23: 245-256.
8. Sader MS, LeGeros RZ, Soares GA. Human osteoblast adhesion and proliferation on magnesium-substituted tricalciumphosphate dense tablets. *J Mater Sci: Mater Med*. 2009; 20: 521-527.
9. Ogose A, Kondo N, Umezu H, Hotta T, Kawashima H, Tokunaga K, Ito T, Kudo N, Hoshino M, Gu W, Endo N. Histological assessment in grafts of highly purified beta-tricalcium phosphate (OSferion ®) in human bones. *Biomaterials*. 2006; 27: 1542-1549.
10. Shalash M, Rahman H, Azim A, Neemat A, Hawary H, Nasry S. Evaluation of horizontal ridge augmentation using beta tricalcium phosphate and demineralized bone matrix: A comparative study. *J Clin Exp Dent*. 2013; 5 (5): e253-9.
11. Capello V. *Rabbit and rodent dentistry handbook*. United State of America: Zoological Education Network, Inc; 2005.
12. Meredith A. Rabbit dentistry. *EJCAP*. 2007; 17 (1): 55-62.