

Histological and Anatomical Structure of The Nasal Cavity of Wild Boar (*Sus scrofa*) from Timor Island

Jania Syelibeth Tanggu¹ , Ingrid Trinidad Maha^{2*} ,
Yulfa N. Selan³ , Heny Nitbani⁴ , Filphin A. Amalo⁵ 

¹Faculty of Medicine and Veterinary Medicine, Nusa Cendana University, Kupang Indonesia

^{2, 3, 4, 5}Department of Anatomy, Physiology, Pharmacology, and Biochemistry Faculty of Medicine and Veterinary Medicine, Nusa Cendana University, Kupang Indonesia

*Corresponding author: maha.i@staf.undana.ac.id

Article history:

Received: 11 December 2025

Revised : 22 January 2026

Accepted: 20 February 2026

Keywords:

wild boar (*Sus scrofa*)
respiratory
olfactory region
respiratory region
vestibular region

ABSTRACT

Background: Wild boars have a important nasal cavity (cavum nasalis) function because it is closely related to their natural behavior to dig into the soil in search of food (rooting behavior). This activity can influence both anatomical and histological characteristics of the nasal cavity and affect the respiratory system.

Aims: This study aims to describe the anatomical and histological features of the nasal cavity of wild boars (*Sus scrofa*) originating from Timor Island through a descriptive and exploratory approach to generate baseline anatomical and histological information.

Methods: Nasal cavities were collected from 2 wild boars (*Sus scrofa*) with healthy criteria from Fatuleu District, Camplong 1, Kupang Regency. The animals were slaughtered, necropsied, macroscopic observations were made on the sagittal section of the wild boar cranium (*Sus scrofa*) to see the structure of the nasal cavities, then the nasal cavities were cut transversely with a thickness of ± 1 cm based on the position of the three regions and fixed in 10% formalin and continued with decalcification using formic acid, then Hematoxylin Eosin (HE) staining was carried out.

Results: The results of the study showed that the nasal cavity of the wild boar (*Sus scrofa*) consists of 3 nasal choncae, namely the dorsal nasal choncha, ventral nasal choncha, and ethmoid choncha. Histologically, the nasal cavity of the wild boar (*Sus scrofa*) consists of three epithelia, namely squamous epithelium, respiratory epithelium (respiration), and olfactory epithelium (smell).

Conclusion: From the results of this study, it can be concluded that the wild boar's nasal cavity consists of three regions, namely the vestibular region, respiratory region, and olfactory region. Squamous epithelium dominates the vestibular respiratory, epithelium respiratorius dominates the respiratory region and region olfactory epithelium dominates the olfactory region.

INTRODUCTION

The population of wild boars is widely distributed in Indonesia, including on Timor Island, and their numbers continue to increase (Kurnia Tohir & Santosa, 2013). The current conservation status of wild boars is classified as least concern, indicating that their population does not face significant threats of extinction (Windasari et al., 2018). Wild boars are able to inhabit various types of

environments, including hilly areas, grasslands, and regions with both tropical and subtropical climates (Harahap et al., 2012). Consequently, many communities in East Nusa Tenggara (NTT) raise wild boars as domesticated animals.

Wild boars possess a relatively small cranium and a long, straight snout (nasal), which enables them to have a highly developed sense of smell (Riwukore & Habaora, 2019). Similar to other pig species, wild boars exhibit

foraging behavior by sensing and sniffing their surroundings using their olfactory sense (Middelkoop et al., 2019). Sniffing behavior represents a common exploratory activity performed by pigs to investigate their environment (Studnitz et al., 2007). As wild animals, wild boars naturally search for food by digging the soil using their snout to obtain tubers and insects (Harahap et al., 2012).

The nasal structure consists of the nasal cavity (cavum nasalis), which has highly complex structural and functional characteristics (Negus, 1958). Structurally, the nasal cavity is composed of the nasal conchae (concha nasalis) and nasal meatus (meatus nasalis) (Peterson et al., 2014). The nasal conchae are lined with a mucosal layer that serves as the first line of defense against respiratory infections, considering that the nasal cavity functions as the primary entry point for pathogens into the respiratory tract (Li et al., 2023). The mucosal epithelium constitutes the structural foundation and the main component of the nasal cavity and acts as the mechanical barrier of the cavum nasalis.

The nasal cavity plays an important role in air filtration, air warming, air humidification, and serves as the main organ responsible for olfaction. According to Harkema et al. (2006), the nasal cavity is susceptible to injury due to the deposition of particulate matter on the nasal epithelium. This vulnerability arises because the nasal cavity functions as the primary site for air filtration. The risk of injury caused by particulate deposition on the nasal epithelium is closely related to the active behavior of wild boars that use their snout to dig the soil in search of food. Therefore, a comprehensive understanding of the anatomical and histological structure of the nasal cavity in wild boars is essential. Such knowledge can serve as a scientific basis for further research development, particularly in efforts to prevent and control respiratory diseases in wild boars.

MATERIALS AND METHODS

The equipment used in this study included a ruler, fixation board, a set of minor surgical instruments (One Med®), incubator, embedding station, rotary microtome, water bath, hot plate, light microscope, and a microscope camera. The samples used in this study consisted of nasal cavities (cavum nasalis) obtained from two wild boars originating from Timor Island aged 1–2 years. The materials used included formic acid, 100 ml of 10% formalin, distilled water (aquadest), graded alcohol solutions (70%, 80%, 90%, and 100%), xylol, paraffin, labeling paper, sample containers, Hematoxylin–Eosin

(HE) staining reagents, entellan, glass slides, cover slips, and tissue cassettes.

The macroscopic observations conducted in this study included the position, average length of the nasal conchae, and the overall structure of the nasal cavity of wild boars. Prior to observation, the nasal cavity was symmetrically sectioned along the nasal septum to separate it into the left (sinister) and right (dexter) halves, allowing assessment of the position and length of the nasal conchae. Following macroscopic examination of the sagittal section of the wild boar cranium, further macroscopic observations were performed on transverse sections of the nasal cavity. The nasal cavity was divided into five transverse sections based on anatomical regions to observe the curvature of the conchae and the nasal meatuses. After fixation, the nasal cavity was divided into four cross-sections (I–V) according to the ratios of 1/20, 1/4, 2/5, 3/5, and 4/5 (as depicted in the pattern diagrams presented in Figure 1B). Cross-section 1/20 and 1/4 corresponded to the vestibular region. Cross-sections 2/5 and 3/5 corresponded to the respiratory region. Cross-section 4/5 corresponded to the olfactory region. After the macroscopic observations, the five transverse sections of the nasal cavity were fixed in 10% formalin for 7 hours. Subsequently, decalcification was carried out for 48 hours using a solution consisting of 10% formalin, formic acid, and distilled water.

Histological Slide Preparation

The cavum nasalis that had been fixed and decalcified was sliced using a scalpel with a thickness of approximately 1 cm, then placed into tissue cassettes and washed under running water for 30 minutes. The process was followed by dehydration using graded alcohols, where the tissues were immersed sequentially in 70%, 80%, 90%, and 100% alcohol, each for 60 minutes at room temperature.

Next, performed sequentially in xylol I, xylol II, and xylol III, each for 45 minutes at room temperature. This was followed by infiltration, where the tissues were immersed in molten paraffin heated at 60°C, repeated three times, each for 60 minutes. The second stage was tissue embedding, where the tissues were embedded in a mold containing molten paraffin on a hot plate until the paraffin hardened. The blocks were then cooled in a refrigerator. Afterward, sectioning was performed by cutting the paraffin blocks into 5 µm thick sections using a microtome, with a cutting angle of 30° relative to the paraffin block. The sections obtained were stretched in a water bath at 50°C, then carefully transferred onto the surface of an object glass (microscope slide). The next step was incubation, which was carried out on a hot plate

at 50°C (below the melting point of paraffin) for 15 minutes.

The following stage was Hematoxylin–Eosin (H&E) staining, a commonly used staining method for observing tissue structure. The first step was deparaffinization of the sections already mounted on the object glass. The slides were immersed in xylol I, xylol II, and xylol III, each for 3 minutes, followed by rehydration in graded alcohols, starting from 100%, 90%, 80%, and 70% alcohol, each for 3 minutes.

After that, the slides were rinsed under running water for 10 minutes. The sections were then immersed in hematoxylin staining solution for 30 minutes, followed by rinsing under running water for 10 minutes. Subsequently, the slides were immersed in eosin staining solution for 5 minutes and rinsed again under running water for 10 minutes. After the staining process was completed, the next step was dehydration using graded alcohols: 70%, 80%, 90%, and absolute alcohol I and II, with the slides immersed in each solution for 30 seconds. This was followed by the clearing process, in which the slides were immersed sequentially in xylol I, xylol II, and xylol III, each for 2 minutes. The final step in the staining procedure was mounting the slides. One drop of Entellan® mounting medium was placed on the preparation, and it was then covered with a cover glass. The slides were allowed to dry and subsequently observed under a microscope.

RESULTS AND DISCUSSION

The anatomical observations showed that the nasal cavity (cavum nasalis) is divided by the nasal septum into the left (sinister) and right (dexter) portions. The nasal cavity of the wild boar consists of three anatomical regions extending from cranial to caudal, namely the vestibular region, respiratory region, and olfactory region (Figure 1). The nasal cavity of the wild boar is composed of nasal conchae and nasal meatuses. There are three nasal conchae in the wild boar nasal cavity, namely the dorsal nasal concha (nasoturbinale), the ventral nasal concha (maxilloturbinale), and the ethmoidal concha (ethmoturbinale) (Figure 1). These

findings are similar to those reported by Yang et al. (2007) regarding the structure of the nasal cavity in Bama miniature pigs. The three nasal conchae form several nasal meatuses, including the dorsal nasal meatus, ventral nasal meatus, and middle nasal meatus (Figures 2, 3, and 4). The three regions of the wild boar nasal cavity exhibit differences in their anatomical structures. The vestibular region is composed of the ventral and dorsal nasal conchae, characterized by relatively simple curvatures. The respiratory region is also formed by the ventral and dorsal nasal conchae but has a more complex structure compared to the vestibular region. Meanwhile, the olfactory region is composed of the dorsal nasal concha and the ethmoidal concha, which display much more developed curvatures than those in the vestibular and respiratory regions.

The nasal cavity (cavum nasalis) of the wild boar has an average length of 16 cm. The dorsal nasal concha is located in the dorsal part of the wild boar nasal cavity, with an average length of 11.4 cm. The ventral nasal concha is situated in the ventral part of the nasal cavity, with an average length of 10.2 cm. Based on observations of sagittal sections of the wild boar cranium, the ventral nasal concha is shorter than the dorsal nasal concha. However, the ventral nasal concha appears wider than the dorsal nasal concha. These findings are consistent with those reported by Yang et al. (2007), who observed that the dorsal nasal concha is longer than the ventral nasal concha in Bama miniature pigs, a condition that optimizes olfactory function because the dorsal nasal concha regulates airflow toward the ethmoidal concha. The ethmoidal concha is located in the posterior part of the wild boar nasal cavity and is present only in the olfactory region, with an average length of 4.9 cm.

The nasal conchae of wild boars exhibit more extensive curvatures than those of Bama miniature pigs described by Yang et al. (2007). This structural condition may contribute to enhanced olfactory and respiratory capabilities in wild boars, as they possess wider respiratory and olfactory regions, thereby increasing the contact between inhaled air and the epithelial lining of the nasal conchae. This ability is likely associated with

Table 1. Average Length of the Nasal Conchae in Wild Boars

Sample	Dorsal nasal concha	Ventral nasal concha	Ethmoidal concha
Wild boar 1	11,2 cm	9,8 cm	4,7 cm
Wild boar 2	11,5 cm	10,5 cm	5 cm
Average	11,4 cm	10,2 cm	4,9 cm

the ecological behavior of wild boars as free-ranging animals that rely on nasal function to locate food, thus requiring optimal olfactory and respiratory performance. In contrast, Bama miniature pigs are domesticated animals and do not require olfactory capabilities to the same extent as wild boars.

The vestibular region of the wild boar nasal cavity appears narrower than the respiratory region (Figure 1). The anatomical structures observed in this region include the ventral nasal concha, dorsal nasal concha, dorsal nasal meatus, ventral nasal meatus, middle nasal meatus, and the nasal meatus (Figure 2). In contrast to the Bama miniature pig, in the 1/20 section of the wild boar nasal cavity (Figure 2A), the dorsal nasal concha was not observed, and the ventral nasal concha that was present did not exhibit complex curvatures. The anatomical features of the vestibular region in the 1/20 section of the wild boar in this study are nearly similar to those of the vestibular region in dogs and rats, as reported by Chamanza & Wright (2015). In the 1/4 section of the vestibular region, the dorsal nasal concha was observed forming the dorsal nasal meatus (Figure 2B). The presence of the dorsal nasal concha allows increased contact between inhaled air and the epithelial lining of the concha, thereby enhancing air processing in the vestibular region. In addition, the 1/4 section also showed a slight medioventral curvature of the ventral nasal concha, forming the middle nasal meatus and the

ventral nasal meatus. The curvature of the ventral nasal concha functions to regulate airflow so that it does not move only in a straight path but is instead redirected and slowed, thereby increasing the contact between inhaled air and the epithelial lining of the ventral nasal concha.

Both the dorsal nasal concha and the ventral nasal concha can be observed in the respiratory region of the wild boar (Figure 3). The dorsal nasal concha in this region does not exhibit curvature, in contrast to the ventral nasal concha, which curves medioventrally. The curvature of the ventral nasal concha plays a role in generating airflow turbulence within the nasal cavity. This turbulence facilitates the trapping of foreign particles on the conchal surface. In addition, the curvature separates the airflow pathway toward the dorsal direction (leading to the olfactory region) and toward the ventral direction (leading to the deeper respiratory region). The dorsal nasal concha in the respiratory region is larger than that in the vestibular region. This structural difference facilitates increased interaction between inhaled air and the epithelial lining of the conchal surface, thereby promoting more effective air processing in this region. The curvature of the ventral nasal concha in the respiratory region of the wild boar observed in this study demonstrates a more complex structure than that reported for the ventral nasal concha in the respiratory region of Bama

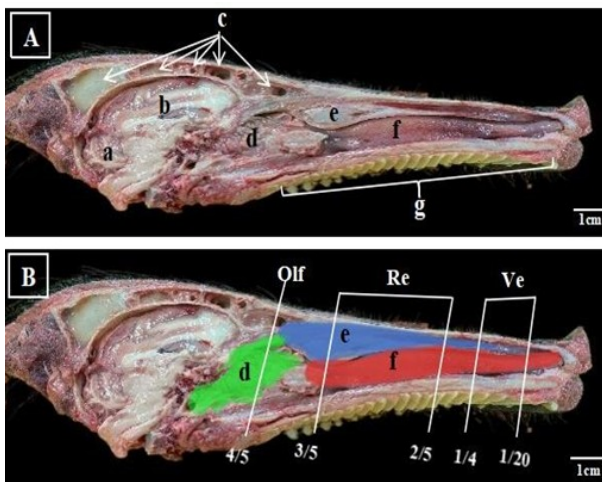


Figure 1. Sagittal Section of the Wild Boar Cranium. (A) Anatomy of the Wild Boar Cranium. (B) Schematic Illustration of the Wild Boar Nasal Cavity. (a) cerebellum, (b) cerebrum, (c) frontal sinus, (d) ethmoidal concha (green), (e) dorsal nasal concha (blue), (f) ventral nasal concha (red), (g) hard palate, Ve: Vestibular Region, Re: Respiratory Region, and Olf: Olfactory Region.

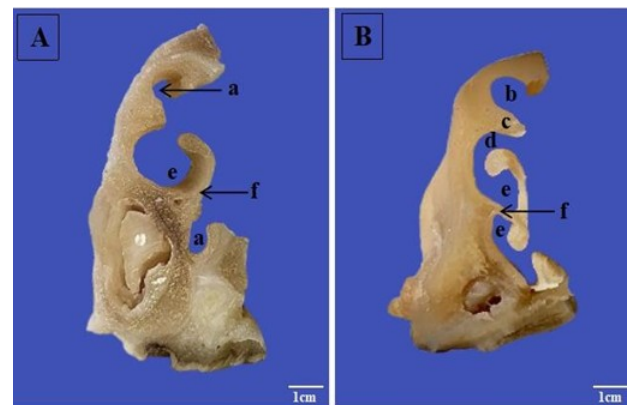


Figure 2. Transverse Section of the Vestibular Region of the Wild Boar. (A) Section at 1/20. (B) Section at 1/4. (a) nasal meatus, (b) dorsal nasal meatus, (c) dorsal nasal concha, (d) middle nasal meatus, (e) ventral nasal meatus, and (f) ventral nasal concha.

miniature pigs by Yang et al. (2007). However, based on observations by Madkour and Abdelsabour-Khalaf (2021), the curvature of the ventral nasal concha in the respiratory region of dogs exhibits a more complex anatomical configuration than that of the wild boar

The olfactory region of the wild boar exhibits a much more complex anatomical structure than the two preceding regions (the vestibular and respiratory regions) (Figure 4). The olfactory region is composed of the ethmoidal concha and the dorsal nasal concha. The ventral nasal concha was not observed in the olfactory region. The dorsal nasal concha in this region is considerably smaller than the dorsal nasal concha found in both the vestibular and respiratory regions. The ethmoidal concha displays more intricate folds (lamellae) compared to the ventral nasal concha (Figure 4). The highly folded structure of the ethmoidal concha in the olfactory region significantly increases the mucosal surface area, which in turn enhances air-processing capacity in this region. Based on the observations in this study, the lamellae of the ethmoidal concha in the wild boar demonstrate a more complex structure than those reported for the ethmoidal concha in the olfactory region of Bama miniature pigs (Yang et al., 2007). These findings suggest that wild boars, as free-ranging animals that rely heavily on olfaction, possess superior olfactory capability compared to Bama miniature pigs, due to the larger epithelial surface area of the ethmoidal concha in wild boars.

Histological observations showed that the nasal cavity of the wild boar is lined by three types of epithelium: squamous epithelium, respiratory epithelium, and olfactory epithelium. These findings are consistent with the report by Chamanza and Wright (2015), who stated that the nasal cavity histology of rodents and dogs is also composed of three epithelial types, namely squamous, respiratory, and olfactory epithelia. The thickness of each epithelial type varies across different regions.

The histology of the vestibular region in the wild boar is dominated by squamous epithelium (Figure 5). This epithelium provides mechanical protection, as the vestibular region is located near the nares and is therefore susceptible to the entry of contaminated air and trauma caused by friction from coarse environmental particles. This condition is relevant to the behavior of wild boars as free-ranging animals that actively use their nasal structures to forage for tubers and insects in the soil. These findings are consistent with the report by Yang et al. (2007), who noted that the vestibular region of Bama miniature pigs is also dominated by squamous epithelium, which functions to provide mechanical protection to the nasal cavity. The squamous epithelium observed in the vestibular region is non-keratinized squamous epithelium (Figure 5B). Similar observations were reported by Harkema et al. (2006) in the vestibular regions of dogs and monkeys, which are also lined by non-keratinized squamous

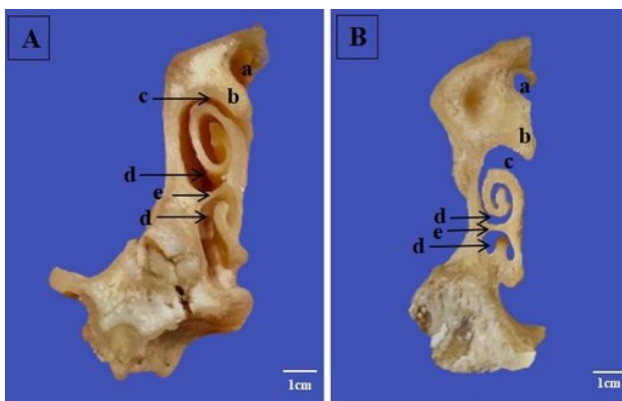


Figure 3. Transverse Section of the Respiratory Region of the Wild Boar. (A) Section at 2/5. (B) Section at 3/5. (a) dorsal nasal meatus, (b) dorsal nasal concha, (c) middle nasal meatus, (d) ventral nasal meatus, and (e) ventral nasal concha.

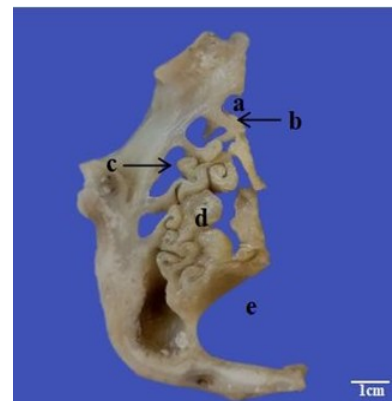


Figure 4. Transverse Section of the Olfactory Region of the Wild Boar (Figure 14). (a) dorsal nasal meatus, (b) dorsal nasal concha, (c) middle nasal meatus, (d) ethmoidal conchal lamella, and (e) nasopharyngeal meatus.

epithelium. Histological observations of the 1/20 section of the vestibular region showed dominance of squamous epithelium, whereas at the ventral base of the ventral nasal concha, a transition from squamous epithelium to columnar epithelium was observed (Figure 5D). Observations of the 1/4 section revealed the presence of columnar epithelium on the ventral nasal concha (Figure 6A) and transitional epithelium at the tip of the dorsal nasal concha (Figure 6C). These findings are comparable to those reported by Yang et al. (2007) in the vestibular region of Bama miniature pigs, which also demonstrated the presence of columnar and transitional epithelia. The squamous epithelium lining the ventral nasal concha in the vestibular region undergoes a transition into densely arranged ciliated columnar epithelium accompanied by goblet cells. This observation is consistent with the statement by Ranslow et al. (2014), who reported that the respiratory region in mammals is lined by tightly arranged columnar cells.

Histologically, the respiratory region of the wild boar is dominated by respiratory epithelium covering

almost the entire surface of both the ventral nasal concha (Figure 7) and the dorsal nasal concha (Figure 8). In addition, this region also exhibits the presence of blood vessels, seromucous glands, seromucous gland ducts, and lymphatic tissue. Ciliated columnar cells and goblet cells function synergistically to maintain the integrity and function of the respiratory epithelium. Goblet cells produce mucus that traps foreign particles. This mucus is subsequently transported by the coordinated movement of cilia on the surface of columnar cells, enabling the removal of trapped particles. The mucus produced by goblet cells also protects the respiratory epithelium from desiccation that may lead to irritation. Basal cells function as stem cells responsible for regenerating epithelial cells that have been injured or damaged.

Histological observations of the ventral nasal concha in the wild boar revealed an abundant vascular network (Figures 9), which facilitates optimal warming of inhaled air through heat transfer from the blood to the incoming air. In addition, the dense and evenly distributed seromucous glands along the curvature of

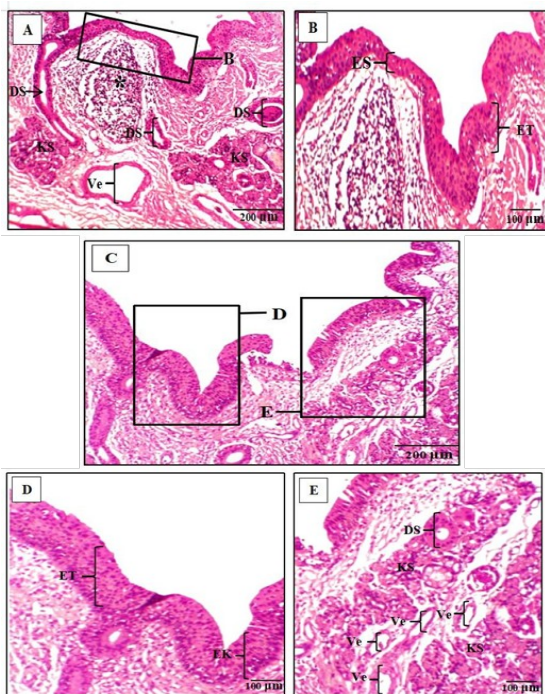


Figure 5. Histology of the Vestibular Region of the Wild Boar, Section 1/20. (A) Lateral aspect of the ventral nasal concha (HE, 10x). (B) Black box insert. (C) Ventral aspect of the ventral nasal concha (HE, 10x). (D–E) Black box inserts. (*): lymphatic tissue, Ve: venule, KS: seromucous gland, DS: seromucous gland duct, ET: transition from squamous epithelium to columnar epithelium, ES: non-keratinized squamous epithelium, and EK: columnar epithelium.

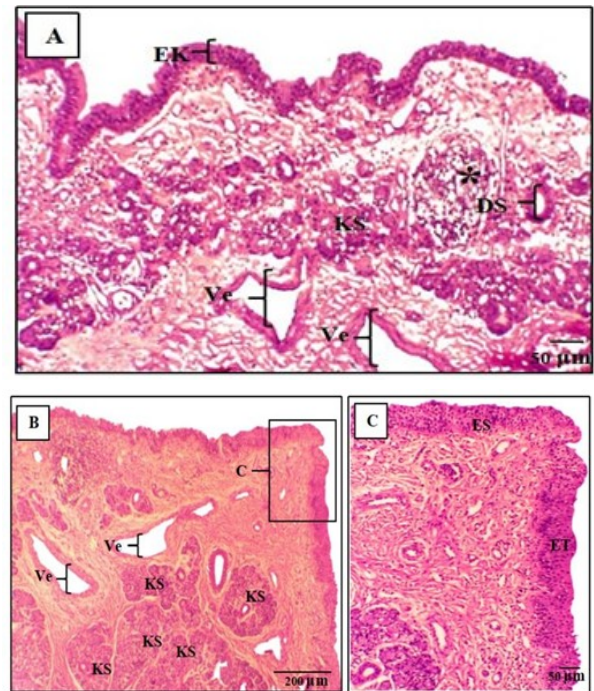


Figure 6. Histology of the Vestibular Region of the Wild Boar, Section 1/4. (A) Ventral nasal concha (HE, 10x). (B) Dorsal nasal concha (HE, 4x). (C) Black box insert (HE, 10x). (*): lymphatic tissue, Ve: venule, KS: seromucous gland, DS: seromucous gland duct, ET: transition from squamous epithelium to columnar epithelium, ES: non-keratinized squamous epithelium, and EK: columnar epithelium.

the ventral nasal concha (Figure 10) enhance both the defensive and humidifying functions of the nasal cavity. Seromucous glands produce mucus as well as serous fluid, which is relatively more fluid than the mucus secreted by goblet cells. The secretions of seromucous glands contain immunoglobulin A (IgA), which plays an important role in trapping and neutralizing invading pathogens. This observation is consistent with the findings of Harkema et al. (2006), who described the lamina propria as being composed of abundant blood vessels and densely packed seromucous glands. Histological examination of the curvature of the ventral nasal concha also revealed the

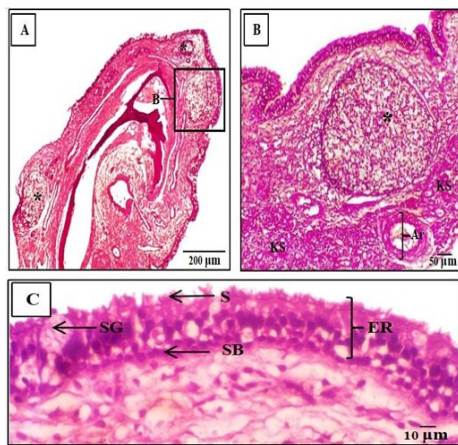


Figure 7. Histology of the Ventral Nasal Concha in the Respiratory Region of the Wild Boar. (A) Tip of the curvature of the ventral nasal concha (HE, 4x). (B) Black box insert (HE, 10x). (C) Respiratory epithelium (HE, 40x). (*): lymphatic tissue, Ar: arteriole, ER: respiratory epithelium, KS: seromucous gland, S: cilia, SB: basal cells, and SG: goblet cells among ciliated columnar cells.

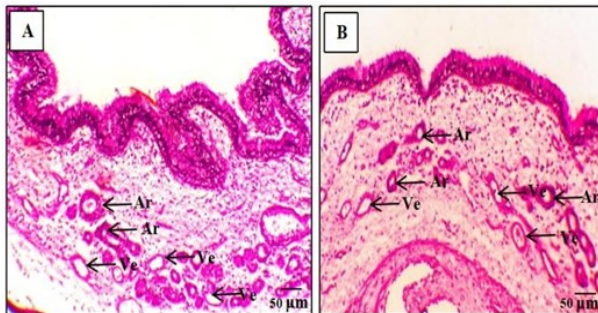


Figure 9. Distribution of Blood Vessels in the Curvature of the Ventral Nasal Concha. (A) Curvature toward the dorsal direction (HE, 10x). (B) Curvature toward the ventral direction (HE, 10x). Ar: arteriole and Ve: venule.

presence of dense lymphatic tissue, likely due to the high accumulation of trapped particles or foreign materials in the respiratory region of the ventral nasal concha, resulting from its curved anatomical configuration (Figure 10). This finding aligns with histological observations of the ventral nasal concha curvature in dogs reported by Chamanza and Wright (2015), who also identified dense lymphatic tissue in this region. The presence of dense lymphatic tissue in this area provides a first line of defense against airborne pathogens. Overall, the histological organization of the lamina propria in the respiratory region—comprising seromucous glands, blood vessels,

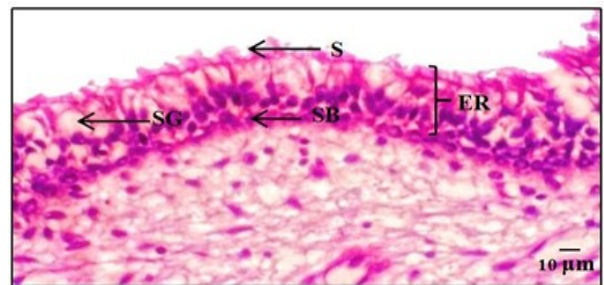


Figure 8. Histology of the Dorsal Nasal Concha in the Respiratory Region of the Wild Boar. S: cilia, SB: basal cells, and SG: goblet cells among ciliated columnar cells (HE, 40x).

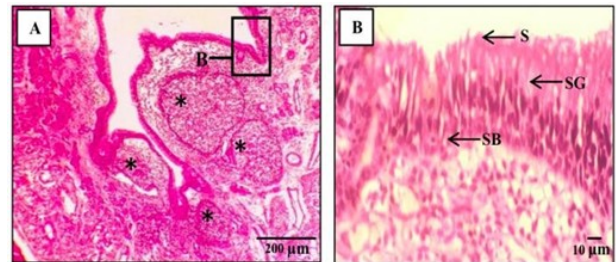


Figure 10. Histology of the Curvature of the Ventral Nasal Concha. (A) Magnification 4x. (B) Black box insert (HE, 40x). (*): lymphatic tissue beneath the respiratory epithelium, S: cilia, SB: basal cells, and SG: goblet cells among ciliated columnar cells.

and dense lymphatic tissue—supports the optimization of respiratory function in wild boars, particularly in the processes of air humidification and warming mediated by the respiratory epithelium.

The olfactory epithelium of the wild boar exhibited three characteristic cell types: sustentacular cells, olfactory receptor cells, and basal cells. Based on the observations, sustentacular cells are located in the superficial layer of the olfactory epithelium and have a columnar shape with pale nuclei. Olfactory receptor cells are situated between sustentacular cells and basal cells, whereas basal cells are located at the deepest layer of the epithelium, directly adjacent to the basal lamina (Figure 11). Basal cells possess dark, small, and round nuclei and function as stem cells responsible for the regeneration of receptor cells following injury or damage. In the lamina propria of the olfactory epithelium, densely packed Bowman's glands were observed. These glands exhibit a pyramidal shape with flattened nuclei and are arranged in a crescent-like pattern. This finding is similar to that reported by Ibrahim et al. (2013) regarding the histological structure of the lamina propria of the olfactory epithelium in sheep.

The histology of the olfactory region in the wild boar is dominated by densely arranged olfactory epithelium lining the ethmoidal concha. The ethmoidal concha exhibits complex lamellae, resulting in an expanded epithelial surface area. This structural condition is associated with the ecological characteristics of wild boars as free-ranging animals that rely heavily on olfaction to locate food sources, thereby requiring well-developed olfactory capabilities. This interpretation is supported by Ranslow et al. (2014), who reported that olfactory

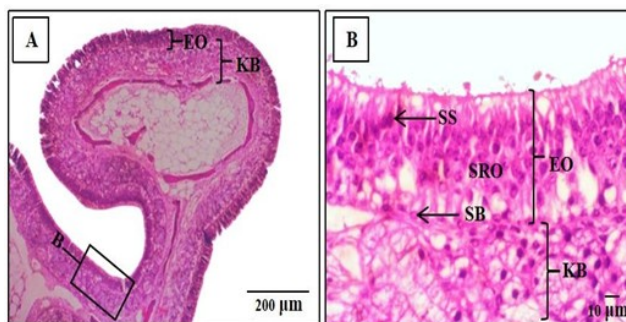


Figure 11. Histology of the Ethmoidal Concha of the Wild Boar. (A) Tip of the ethmoidal concha (HE, 4×). (B) Black box insert (HE, 40×). EO: olfactory epithelium, KB: Bowman's gland, SB: basal cells, SRO: olfactory receptor cells, and SS: sustentacular cells.

epithelium is evenly distributed along the ethmoidal conchae in animals that depend on their sense of smell. Similarly, rodents are characterized by dense olfactory epithelial coverage. Bowman's glands were observed to be densely packed and widely distributed within the lamina propria of the olfactory epithelium (Figure 10). This finding is consistent with the observations of Chamanza and Wright (2015), who reported that animals with strong olfactory reliance, such as dogs, exhibit tightly arranged and abundant Bowman's glands within the lamina propria of the olfactory epithelium. Bowman's glands play a crucial role in supporting olfactory cell function by secreting odorant-binding proteins that facilitate odor detection.

Respiratory epithelium was identified on the ventral aspect of the lamellae of the ethmoidal concha (Figure 12). This area represents a transitional zone between the respiratory and olfactory regions. The respiratory epithelium in this region is thinner than that observed in the preceding regions but demonstrates a higher density of goblet cells. These findings align with the observations of Harkema et al. (2006), who reported the presence of respiratory epithelium with dense goblet cell distribution on the ventral aspect of the ethmoidal concha in dogs and monkeys. The mucus and ciliary activity of the respiratory epithelium in this transitional zone are thought to contribute to odor dissolution and to protect the olfactory region from foreign particles (Harkema et al., 2006). In addition, a greater density of blood vessels was observed in this region, likely supporting the warming of inhaled air.

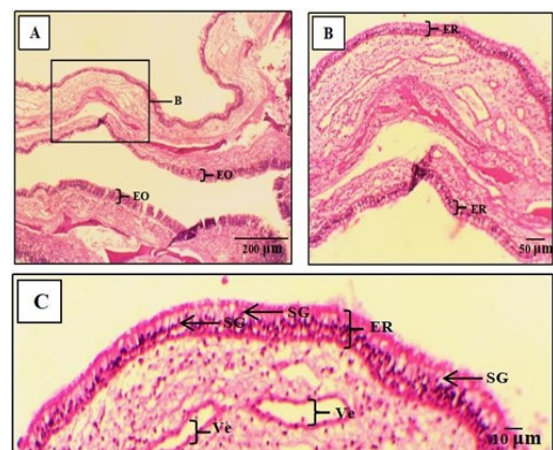


Figure 12. Histology of the Lamella of the Ethmoidal Concha of the Wild Boar. (A) Epithelium lining the lamella of the ethmoidal concha (HE, 4×). (B) Black box insert (HE, 10×). (C) Respiratory epithelium (HE, 40×). EO: olfactory epithelium, ER: respiratory epithelium, SG: goblet cells, and Ve: venule.

CONCLUSION

From the results of this study, it can be concluded that the nasal cavity (cavum nasalis) of the wild boar consists of three nasal conchae: the ventral nasal concha (concha nasalis ventralis), the dorsal nasal concha (concha nasalis dorsalis), and the ethmoidal concha (concha ethmoidalis). The ventral nasal concha is present in the vestibular and respiratory regions, while the dorsal nasal concha is found in the vestibular, respiratory, and olfactory regions. In contrast, the ethmoidal concha is located in the olfactory region. These three conchae exhibit different curvatures in each region.

Histologically, the nasal cavity of the wild boar is composed of three types of epithelium: squamous epithelium, respiratory epithelium, and olfactory epithelium, each predominating in specific regions. The olfactory epithelium predominates in the olfactory region, the respiratory epithelium predominates in the respiratory region, and the squamous epithelium predominates in the vestibular region.

The respiratory epithelium consists of ciliated columnar cells, goblet cells, and basal cells. The lamina propria of the respiratory epithelium contains dense seromucous glands, abundant vascularization, and lymphatic tissue. The olfactory epithelium is composed of sustentacular cells, olfactory receptor cells, and basal cells. The lamina propria of the olfactory epithelium contains densely distributed Bowman's glands.

AUTHORS CONTRIBUTION

J.S.T. conducted sample collection, performed laboratory and histological procedures, analyzed the data, and drafted the manuscript. I.T.M. contributed to research supervision, methodological design, and critical revision of the manuscript. Y.N.S., B.N., and E.A.A. assisted in histological examination, data interpretation, and manuscript editing. All authors contributed to the study conception and design, read and approved the final version of the manuscript, and agreed to be accountable for the work.

“The authors declare that there is no conflict of interest with any parties in this research”.

REFERENCES

- Chamanza, R., & Wright, J. A. (2015). A Review of the Comparative Anatomy, Histology, Physiology and Pathology of the Nasal Cavity of Rats, Mice, Dogs and Non-human Primates. Relevance to Inhalation Toxicology and Human Health Risk Assessment. *Journal of Comparative Pathology*, 153(4), 287–314. <https://doi.org/10.1016/j.jcpa.2015.08.009>
- Chulayo, A. Y., Tada, O., & Muchenje, V. (2012). WellBeing International WellBeing International WBI Studies Repository WBI Studies Repository 2012 Research on pre-slaughter stress and meat quality: A review of Research on pre-slaughter stress and meat quality: A review of challenges faced under practic. November, 1–6. www.sasas.co.za/aahrd/
- Djari, D. C., Maha, I. T., & Novian, D. R. (2024). Studi Morfologi Kelenjar Parotis dan Mandibularis Babi Hutan (*Sus scrofa*). *Jurnal Veteriner Nusantara*, 7(1), 1-17.
- Harahap, W.H., Patana P. & Affuddin Y. (2012). Mitigasi Konflik Satwa Liar dengan Masyarakat di Sekitar Taman Nasional Gunung Leuser. Artikel. Fakultas Pertanian, Universitas Sumatera Utara, Medan.
- Harkema, J. R., Carey, S. A., & Wagner, J. G. (2006). The Nose Revisited: A Brief Review of the Comparative Structure, Function, and Toxicologic Pathology of the Nasal Epithelium. *Toxicologic Pathology*, 34(3), 252–269. <https://doi.org/10.1080/01926230600713475>.
- Ibrahim, D., Nakamuta, N., Taniguchi, K., Yamamoto, Y., & Taniguchi, K. (2014). Histological and lectin histochemical studies on the olfactory and respiratory mucosae of the sheep. *Journal of Veterinary Medical Science*, 76(3), 339-346.
- Kumar, P., Abubakar, A. A., Imlan, J. C., Ahmed, M. A., Goh, Y. M., Kaka, U., Idrus, Z., & Sazili, A. Q. (2023). Importance of Knife Sharpness during Slaughter: Shariah and Kosher Perspective and Scientific Validation. *Animals*, 13(11), 1–18. <https://doi.org/10.3390/ani13111751>
- Kurnia Tohir, R., & Santosa, Y. (2013). Kajian Potensi Pemanfaatan Babi Hutan (*Sus scrofa*) Selain Sebagai Satwa Buru Dan Rekreasi. *Jurnal Penelitian Institut Pertanian Bogor*, 2(Oliver 1993), 1–5.

- Li, Y., Yang, C., Jiang, Y., Wang, X., Yuan, C., Qi, J., & Yang, Q. (2023). Characteristics of the nasal mucosa of commercial pigs during normal development. *Veterinary Research*, 1–18. <https://doi.org/10.1186/s13567-023-01164-y>.
- Madkour, F., & Abdelsabour-Khalaf, M. (2021). Gross anatomical and morphometrical study of the nasal cavity (cavum nasi) of Egyptian goat (*Capra hircus*) and Egyptian Baladi dog (*Canis lupus*). *SVU-International Journal of Veterinary Sciences*, 4(3), 80–93. <https://doi.org/10.21608/svu.2021.86098.1134>
- Middelkoop, A., Marwijk, M. A. Van, Kemp, B., & Bolhuis, J. E. (2019). Pigs Like It Varied ; Feeding Behavior and Pre- and Post-weaning Performance of Piglets Exposed to Dietary Diversity and Feed Hidden in Substrate During Lactation. 6(November),1–20. <https://doi.org/10.3389/fvets.2019.00408>
- Negus, V.E. (1958) *Comparative Anatomy and Physiology of the Nose and Paranasal Sinuses*. Churchill Livingstone, London.
- Peterson, L. W., & Artis, D. (2014). Intestinal epithelial cells: regulators of barrier function and immune homeostasis. *Nature reviews immunology*, 14(3), 141–153.
- Ranslow, A. N., Richter, J. P., Neuberger, T., Quigley, A. P., Pang, B., Krane, M. H., & Craven, B. A. (2014). Reconstruction and Morphometric Analysis of the Nasal Airway of the White-Tailed Deer (*Odocoileus virginianus*) and Implications Regarding Respiratory and Olfactory Airflow. *Anatomical Record*, 297(11), 2138–2147. <https://doi.org/10.1002/ar.23037>
- Riwukore, J. R., & Habaora, F. (2019). Display of local pig reproduction in East Nusa Tenggara, Indonesia. *International Journal of Agriculture, Environment and Bioresearch*, 4(3), 223–233.
- Setiawan, B. (2016). Optimalisasi Metode Automatic Slide Stainer Untuk Pewarnaan Jaringan Menggunakan Haemotoksilin-Eosin.
- Studnitz, M., Jensen, M. B., & Pedersen, L. J. (2007). Why do pigs root and in what will they root?. A review on the exploratory behaviour of pigs in relation to environmental enrichment. *Applied Animal Behaviour Science*, 107(3–4), 183–197. <https://doi.org/10.1016/j.applanim.2006.11.013>
- Windasari, S. (2018). Estimasi Populasi Babi Hutan (*Sus scrofa*) Berdasarkan Keberadaan Sarang untuk Melahirkan. *Jurnal Biologi Pertanian*, 3(2), 18–29.
- Yang, J., Dai, L., Yu, Q., & Yang, Q. (2017). Histological and anatomical structure of the nasal cavity of Bama minipigs. *PLoS ONE*, 12(3), 1–14. <https://doi.org/10.1371/journal.pone.0173902>