

Canine benign hyperplasia prostate on male pug dog

Zulfa Ichsanniyati R.Ciwi Fadhlillah^{1,*}, I Nengah Yogiswari¹, Siti Zaenab¹,
Deni Noviana^{1,2,3}, Sukmasari Arifah¹

¹ My Vets Animal Clinic Jakarta

² Division of Radiology and Surgery, Faculty of Veterinary Medicine, IPB University, Bogor

³ Veterinary Teaching Hospital, Faculty of Veterinary Medicine, IPB University, Bogor

ABSTRACT: An 9-years-old male pug was examined for stranguria and letargic in one week. The dog has no testicles as the owner claimed that the dog had been castrated a few years ago. Abdominal palpation shows bladder retention filled with urine but no blockage was found. Urine sedimentation contained blood and few unknown crystal. Hematology showed mild anemia and leukocytosis while blood chemistry only found mild hyperglobulinemia. Radiography showed prostate enlargement. Ultrasound examination was showing mild nephrolithiasis, cystitis and prostatic enlargement. Diagnosis of benign prostate hyperplasia is suspected but doubtful because the animal has been castrated. Differential diagnose was prostatic cysts, infection and cancer. The dog received finasteride 1 mg/kg twice a day orally for 60 days and antibiotic. Urine catheter was temporarily installed to evacuate urine twice a day. Post treatment ultrasound was performed 20 days later and showed evident involution of prostate sizes. An enlarge irregular testicle was also found in right dorsolateral of bladder. Monorchid castration was performed at 60 days of finasteride. The dog was diagnosed with monorchid induce benign prostate hyperplasia from the radiography and ultrasonography. The prostate size was reduced after finasteride administration.

Keywords:

canine benign prostate hyperplasia, monorchid, finasteride, pug dog

■ INTRODUCTION

The prostate gland is a bilobed, oval gland located in the pelvic cavity of adult dogs through which passes the urethra and the vas deferens, where the sperm are carried to the urethra. The prostate is stimulated by the testosterone produced by testicles and converted into dihydrotestosterone (DHT) by the enzyme 5 α -reductase (Leis-Filho & Fonseca-Alves 2018).

Castrated dogs lack testosterone and consequently DHT will lead to the prostate to a state atrophy (Adel & Khadidja 2017). Canine prostatic disorders include benign prostatic hyperplasia (BPH), prostatic squamous metaplasia, prostatic cysts, prostatic inflammation, prostatic abscess, prostatic neoplasia (Adel & Khadidja 2017). Prostatic neoplasia is androgen independent so it may affecting both castrated and non-castrated animal (Adel & Khadidja 2017; Paclikova *et al.* 2006).

All prostatic disorders generally observed in dog older than 6 years old, appear as enlargement of the glands that suppress the surrounding organs namely the rectum and urethra. Clinical signs may range from stranguria-dysuria, fecal tenesmus, urethral discharge, and systemic symptoms including depression, lethargy, fever, anorexia, pain and weight loss for prostatic neoplasia. Diagnose is done by taking anamnesis of castration history and the main com-

plaint about the presence of urination and defecation disorder and observed clinical symptoms as mentioned previously (Adel & Khadidja 2017; Paclikova *et al.* 2006). Bladder retention may be found in abdominal palpation, and protrusion of the prostate gland will be palpated on ventral rectal palpation. Hematology to evaluate presence of inflammation and infection from leukocytosis with left shift neutrophilia in acute or within normal in chronic disease while biochemical parameters are not specific in patients without systemic alteration. Urinalysis is performed to evaluate the presence of blood, leukocytes, urinary sediment and overall epithelial cells (Adel & Khadidja 2017; Paclikova *et al.* 2006).

Radiology is the first-choice method in evaluation of position, size and outer surface of the prostate. The prostate is considered enlarged when the prostatic diameter, as visualized on the lateral radiographic view, is greater than 70% of the pubicsacral promontory distance (Feeney *et al.* 1987). The more prostate gland grows; it subsequently obturates pelvic inlet compromising distal colon and rectum, often clearly visible on the x-rays. Thoracic radiography is necessary if metastatic prostatic neoplasia is suspected (Paclikova

Diterima: 28-06-2019 | **Direvisi:** 03-08-2019 | **Disetujui:** 10-08-2019

© 2019 CC-BY-SA. Ini adalah artikel *Open Access* yang didistribusikan berdasarkan ketentuan dari *Creative Commons Attribution ShareAlike 4.0 International License* (<https://creativecommons.org/licenses/by-sa/4.0/>).

et al. 2006). Ultrasound examination marked by increase hyperechogenosity and volume of prostatic gland as well to find testicle in case of cryptorchid (Yehia & Salem 2015). Biopsy may need to perform if no response with the primary treatment.

Finasteride is 5-alpha reductase inhibitory as primary medication 1 mg/kg/day, po for 16 – 21wk to reduce prostatic hyperthropy and resolve clinical sign. Antibiotic and anti inflammation would be necessary if there is sign of infection and inflammation. Castration should be recommended for any prostatic disorders mainly BPH (Adel & Khadidja 2017; Paclikova *et al.* 2006). Euthanasia should be considered for metastatic prostatic neoplasia as no curable treatment available (Adel & Khadidja 2017; Paclikova *et al.* 2006).

■ CASE REPORT

An 9-years-old male pug dog was examined for stranguria and lethargic in one week. The dog has no testicles as the owner claimed that the dog had been castrated a few years ago. Abdominal palpation shows bladder retention filled with urine but no blockage was found. Urine sedimentation contained blood and few unknown crystal. Hematology showed mild anemia and leukocytosis while blood chemistry only found mild hyperglobulinemia. Radiography showed prostate enlargement (Figure 1).

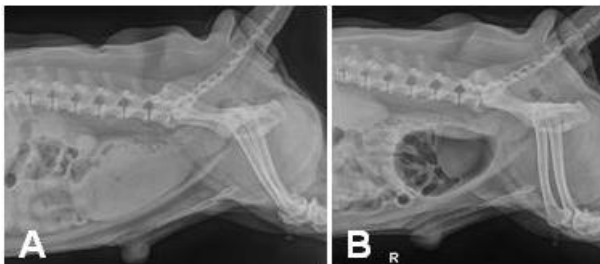

Figure 1 Right latero-lateral plain (A) and negative contrast bladder-urethral (B) radiography showed prostatic enlargement with no cystitis and urethral obstruction.

Ultrasound examination was showing cystitis and prostatic enlargement (Figure 2A). Diagnosis of benign prostate hyperplasia is suspected but doubtful because the animal has been castrated. Differential diagnose was prostatic cysts, infection and cancer. The dog received finasteride 1 mg/kg twice a day orally for 60 days and antibiotic. Urine catheter was temporarily installed to evacuate urine twice a day. Post treatment ultrasound 20 days after treatment showed evident of prostate sizes involution (Figure 2B).

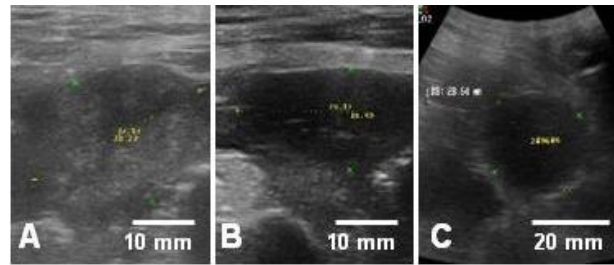


Figure 2. Ultrasound image of prostatic enlargement (A), ultrasound image of involution prostate after 32 days finasteride (B), and ultrasound image of monorchid testicle (C).

An enlarge irregular testicle was also found in right dorso-lateral of bladder (Figure 2C). Monorchid castration was performed at 60 days of finasteride. Ultrasound checkup 2 month after the surgery shows no abdominal organ abnormality.

■ CONCLUSION

The dog was diagnosed with monorchid induce benign prostate hyperplasia from the radiography and ultrasonography. The prostate dog size was reduced after finasteride administration.

■ AUTHOR INFORMATION

Corresponding Author

*ZIRCF: zulfa.koshka@gmail.com
My Vets Animal Clinic, Jakarta, Indonesia

Author Contributions

These authors contributed equally

■ REFERENCES

- Adel A, Khadidja M. 2017. Canine prostatic disorders. *Veterinary Medicine-Open Journal*. 2(3):83-90.
- Feeney DA, Johnston GR, Klausner JS, Perman V, Leininger JR, Tomlinson MJ. 1987. Canine prostatic disease--comparison of radiographic appearance with morphologic and microbiologic findings: 30 cases (1981-1985). *Journal of the American Veterinary Medical Association*. 190(8):1018-1026.
- Leis-Filho AF, Fonseca-Alves CE. Anatomy, histology, and physiology of the canine prostate gland. *In Veterinary Anatomy and Physiology* 2018 Nov 5. IntechOpen.
- Paclikova K, Kohout P, Vlasin M. 2006. Diagnostic possibilities in the management of canine prostatic disorders. *Veterinarni medicina-praha-*. 51(1):1-13.
- Yehia SG, Salem NY. 2015. Ultrasonographic abnormalities in canine urinary and prostatic affections. *Res. J. Vet. Pract.* 4(3):93-98.